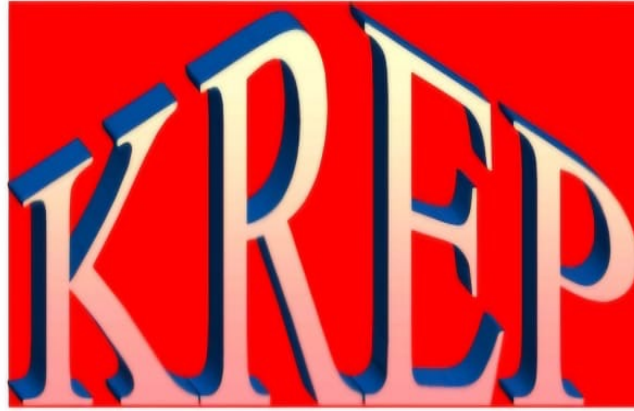


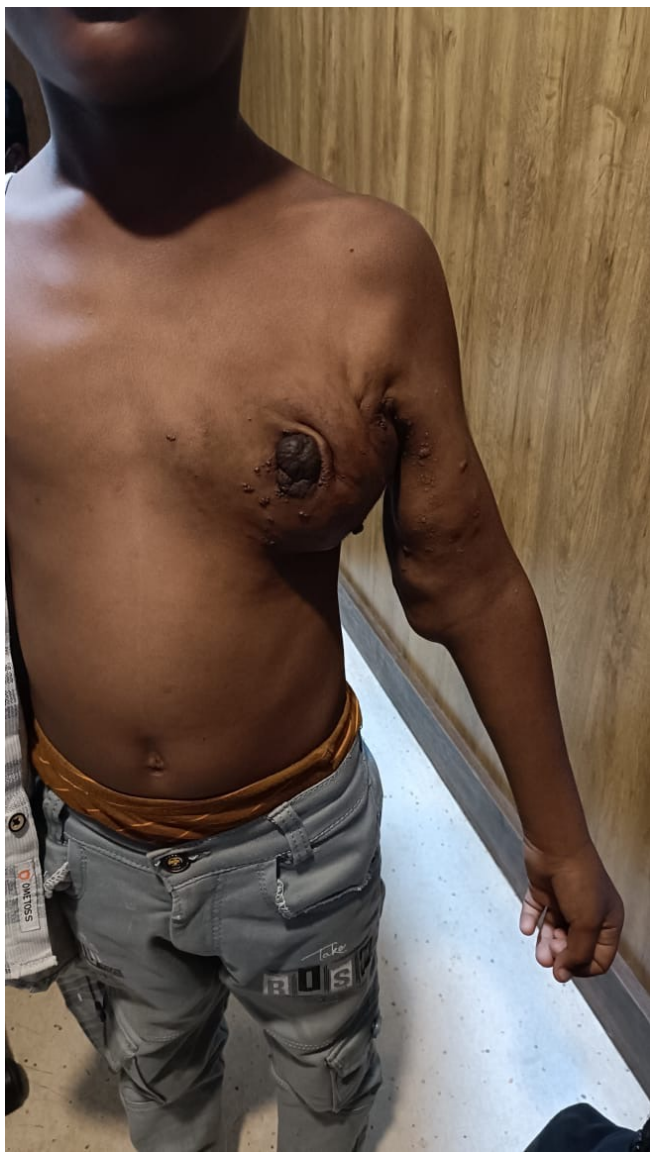
KARNATAKA RADIOLOGY EDUCATION PROGRAM

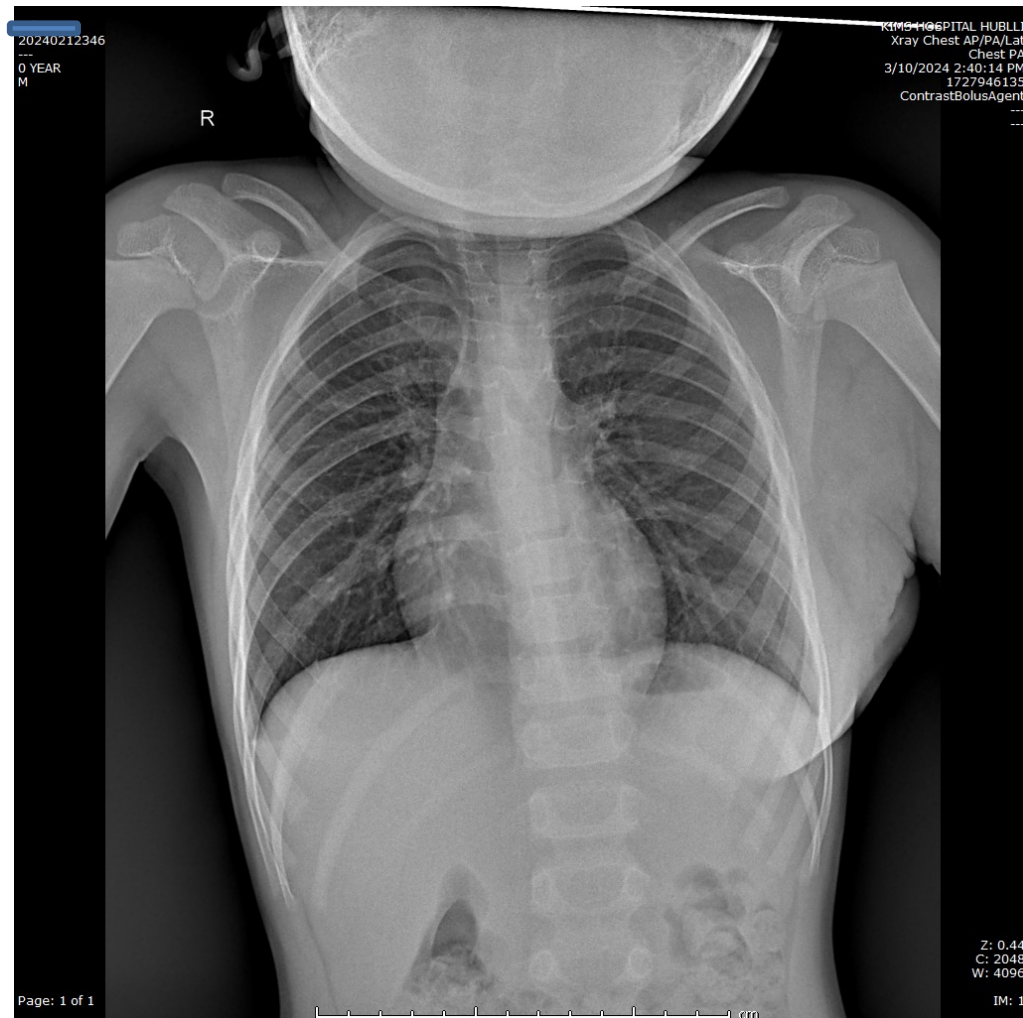
CASE PRESENTATION

MENTOR: DR G C PATIL SIR
KMCRI, HUBBALLI.

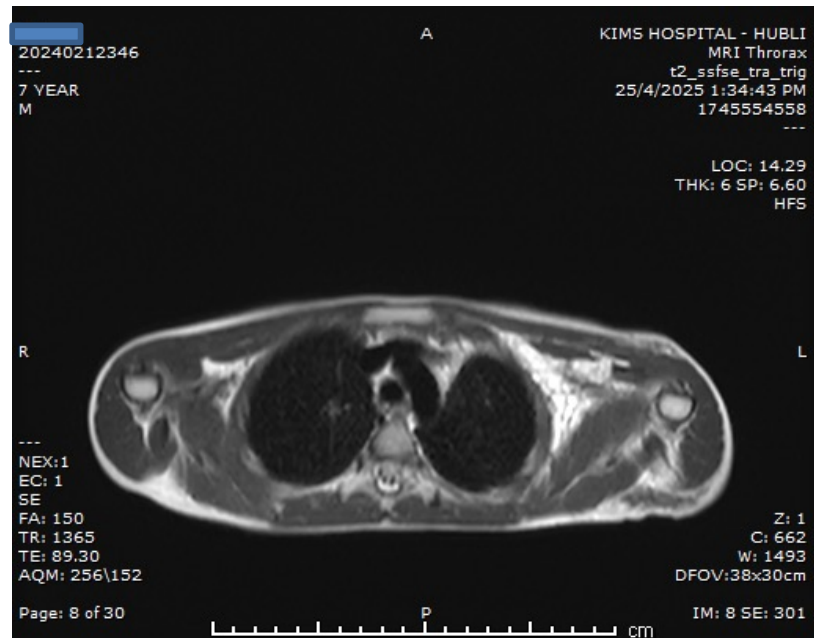
- Name: Master X
 - Age: 7 years 8 months
 - Sex: Male
-
- Chief complaints: Swelling on left side of chest since birth
 - Discharge from pus – 1 day



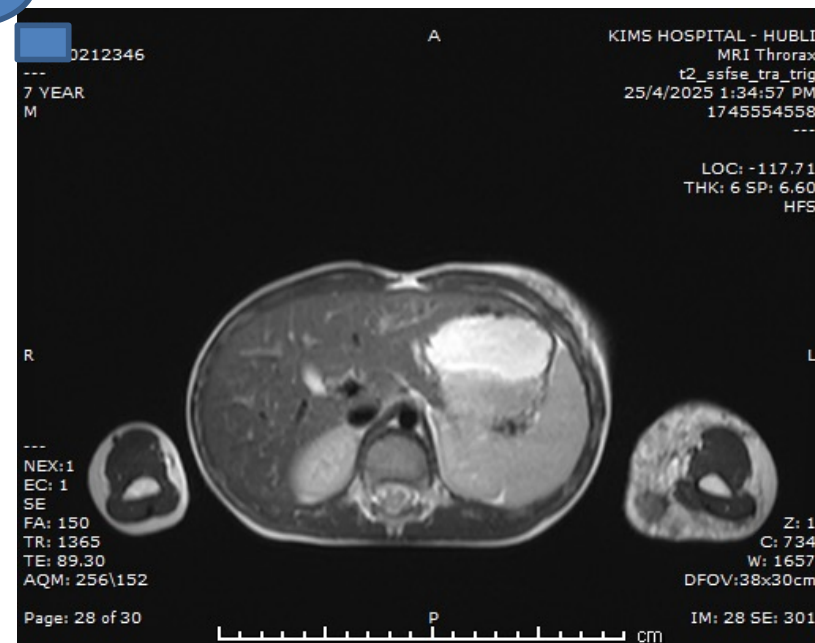
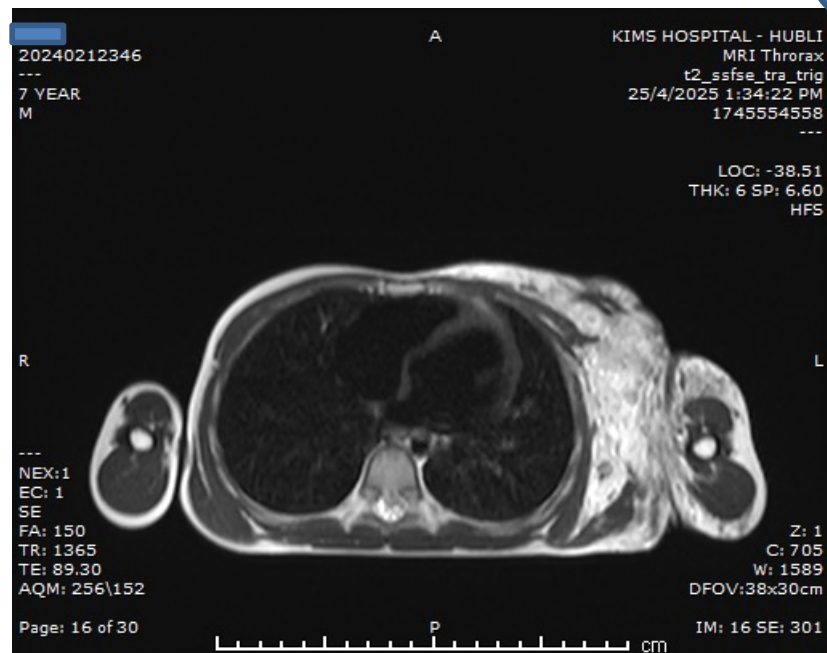
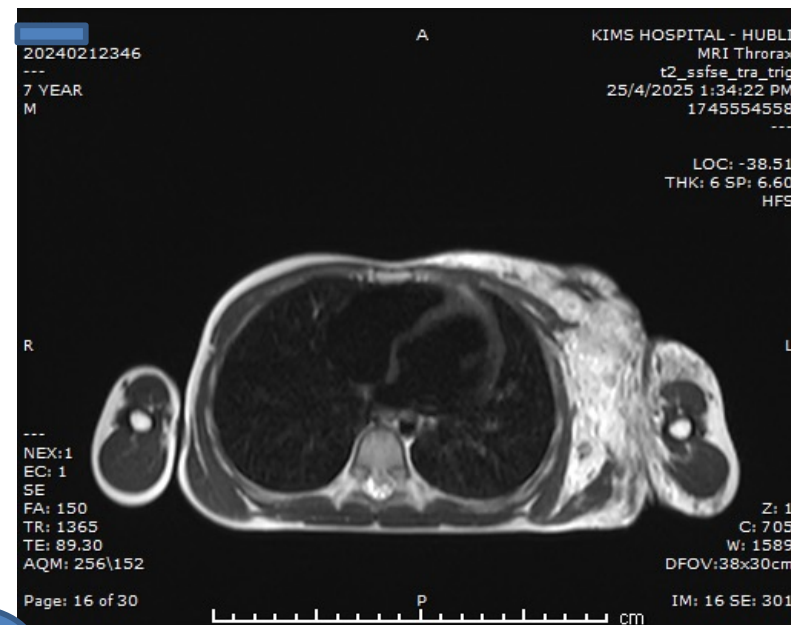
Chest Radiograph

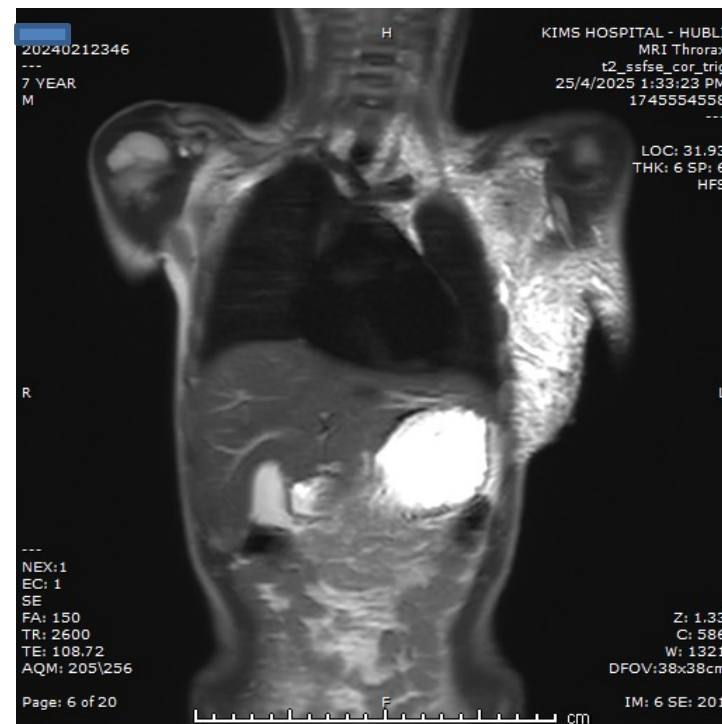
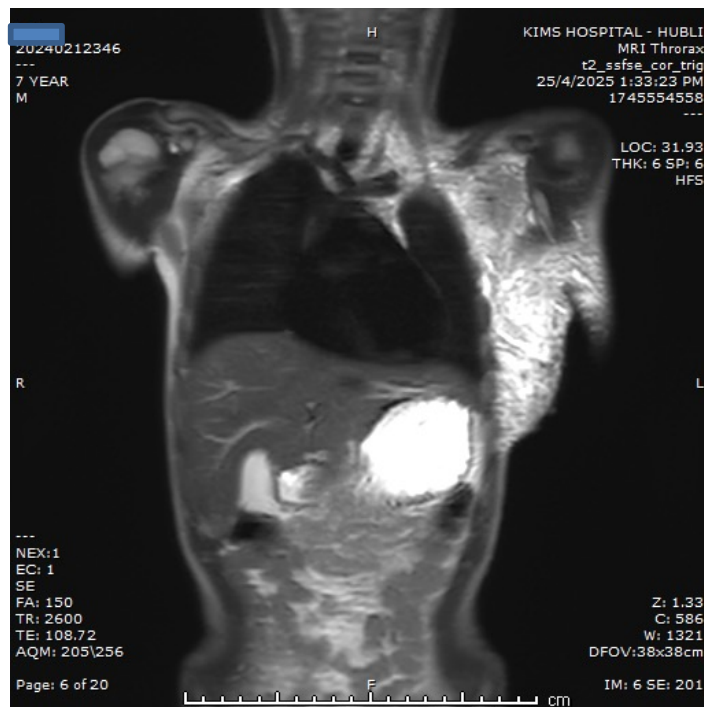
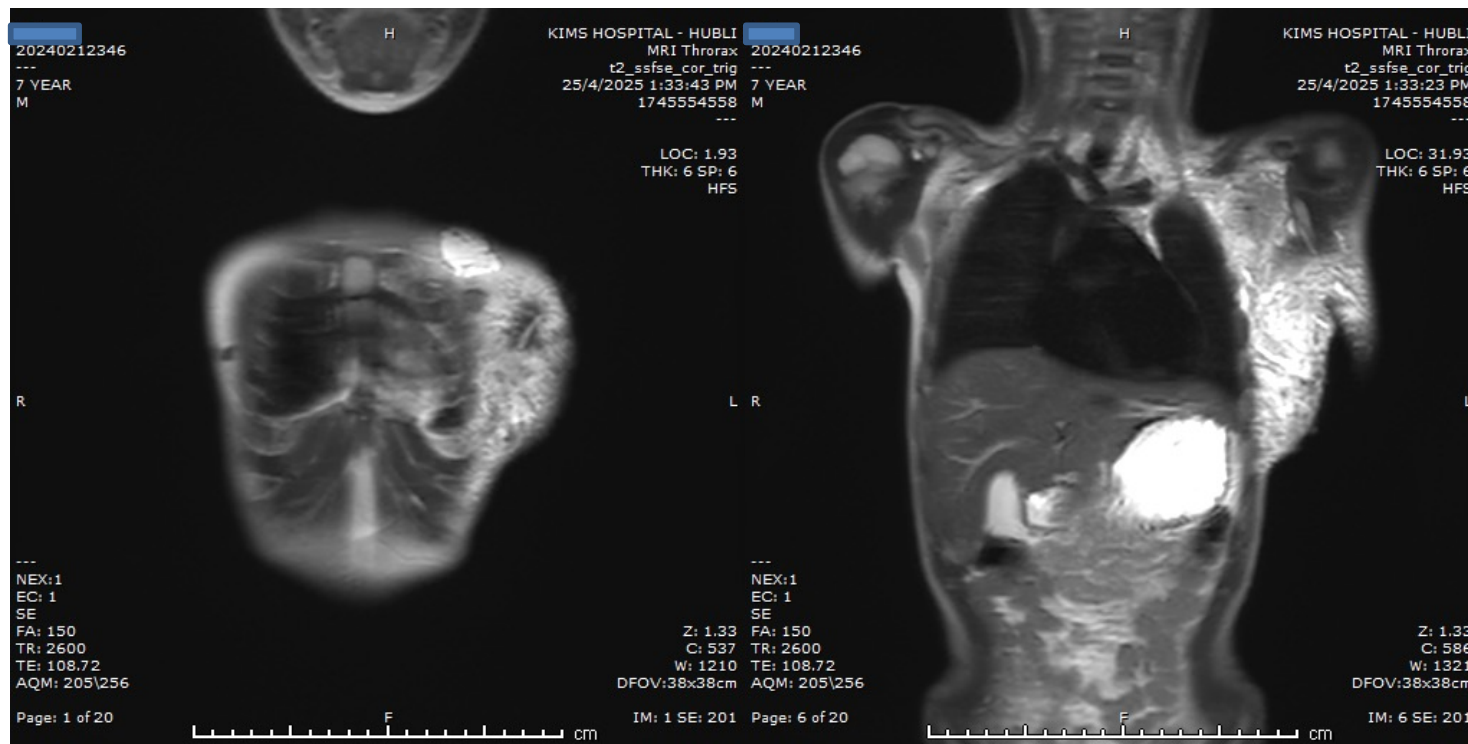


Magnetic Resonance Imaging

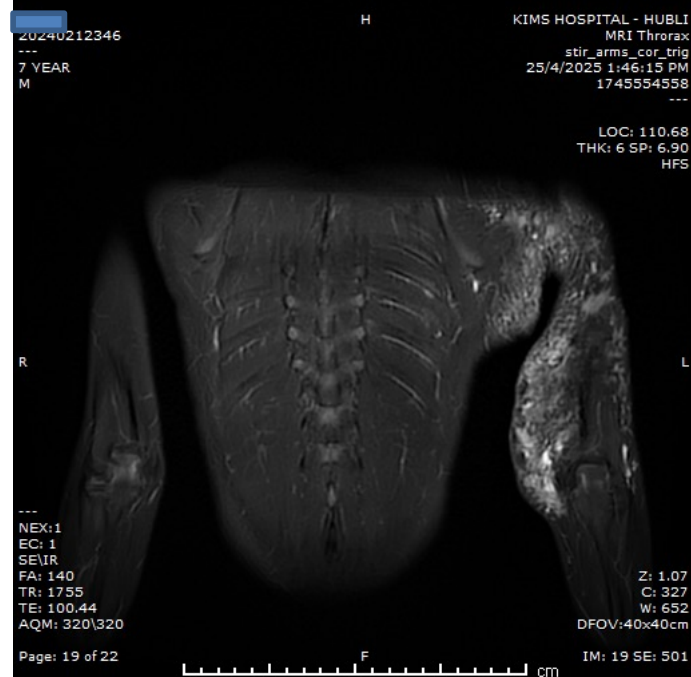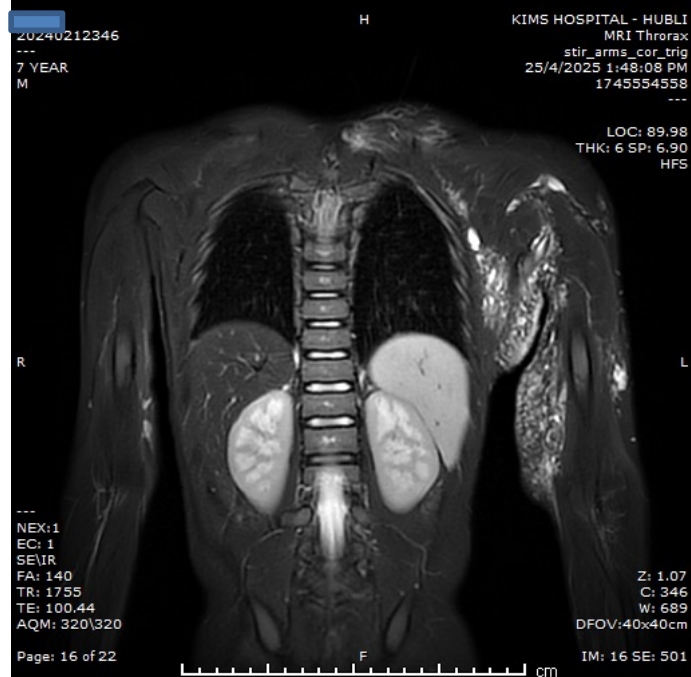
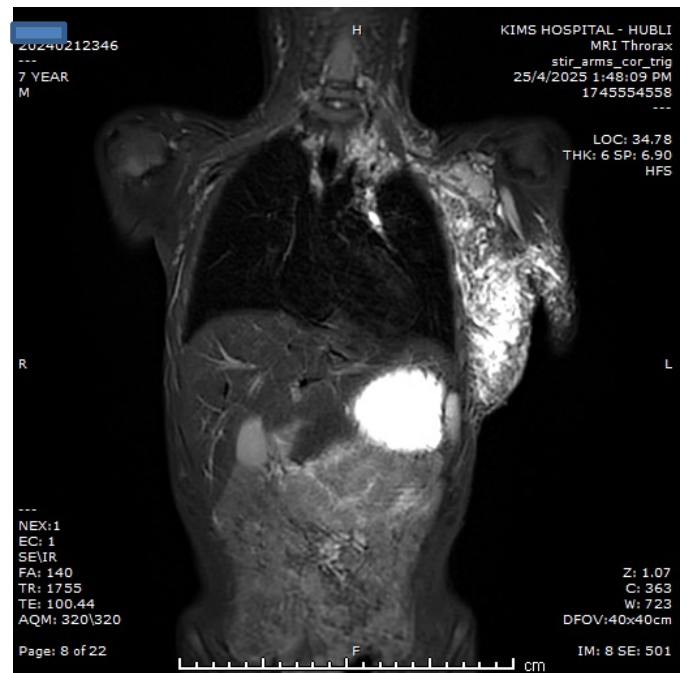
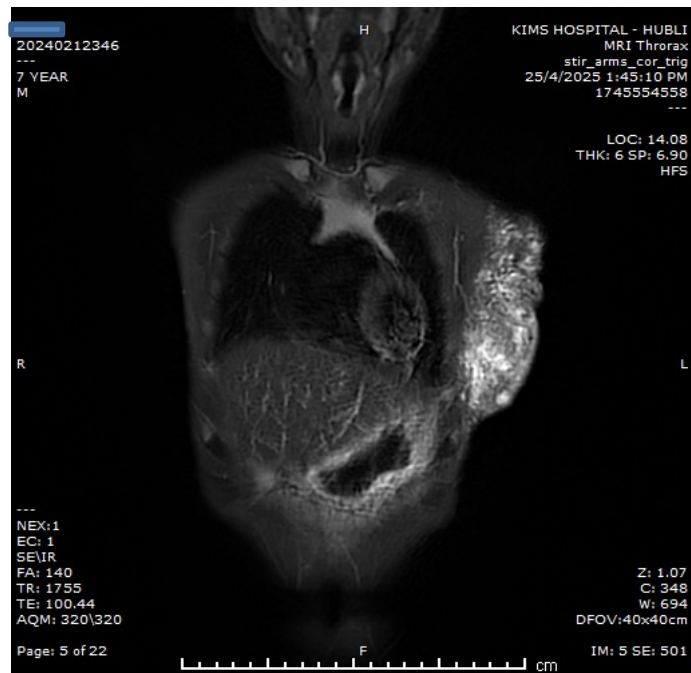


T2

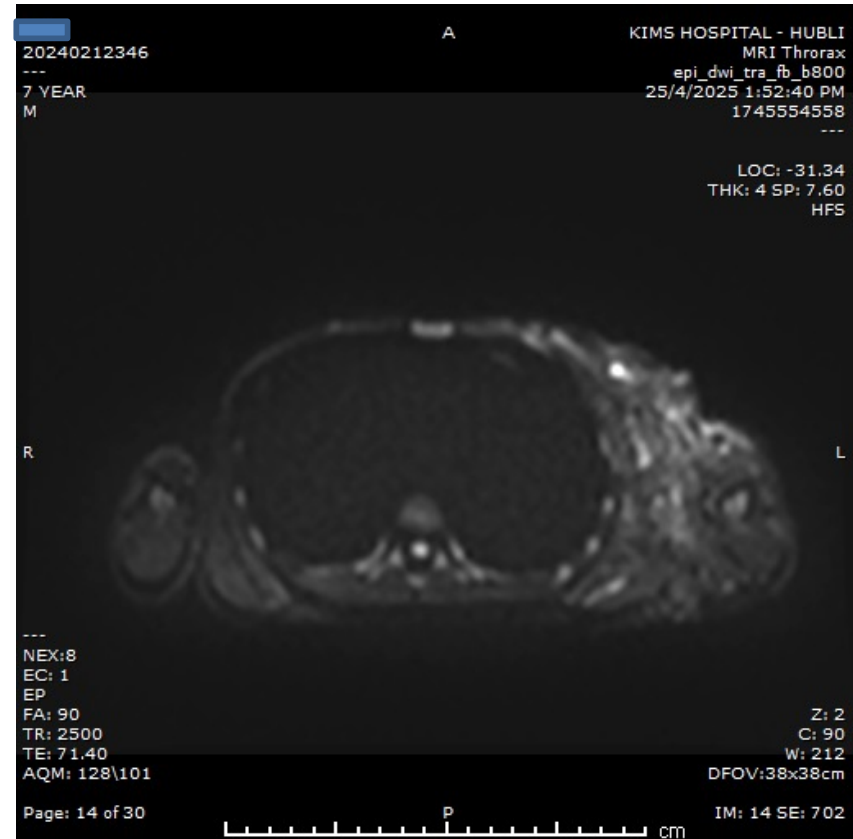
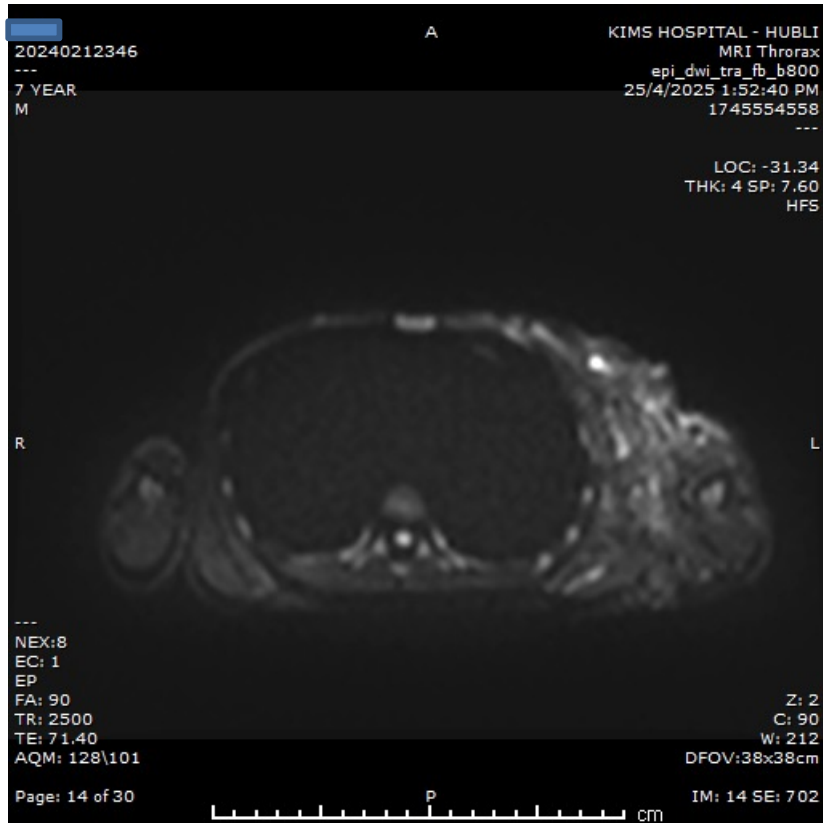




STIR



DWI & ADC



E/o T1 hypointense, T2/STIR hyperintense, ill-defined area involving the left lateral chest wall, left anterior chest wall, axilla, part of scapular region and anterior and medial compartment of arm with few fluid-fluid level **F/S/O**
LYMPHATIC MALFORMATION.

