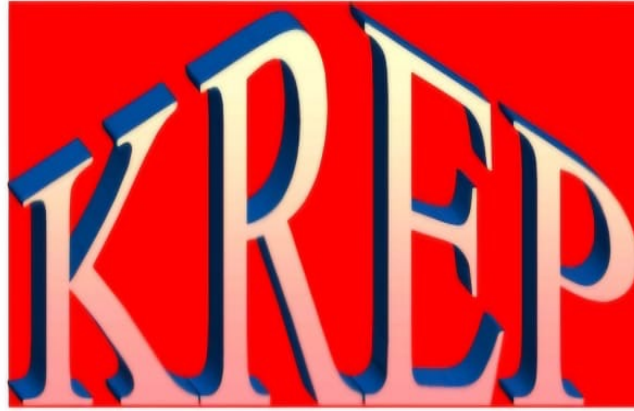



KARNATAKA RADIOLOGY EDUCATION PROGRAM

CASE PRESENTATION

MENTOR: DR G C PATIL SIR
KMCRI,HUBBALLI.

- Master Z
- Age: 4 months
- Chief complaint: Seizure disorder under evaluation

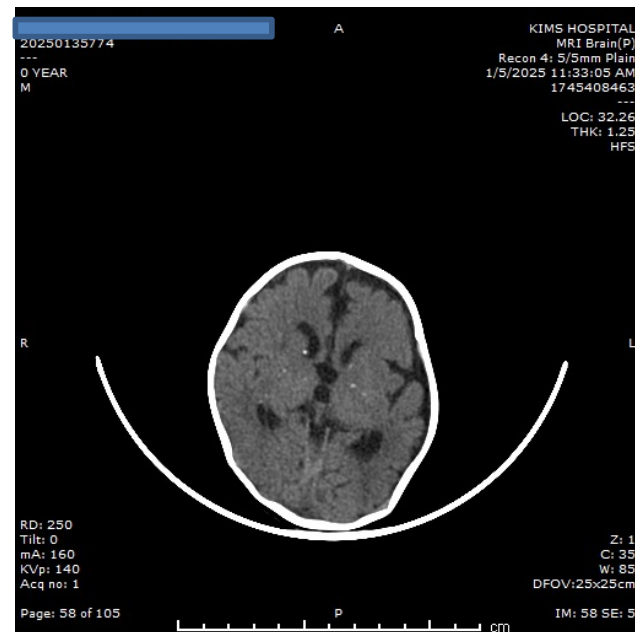
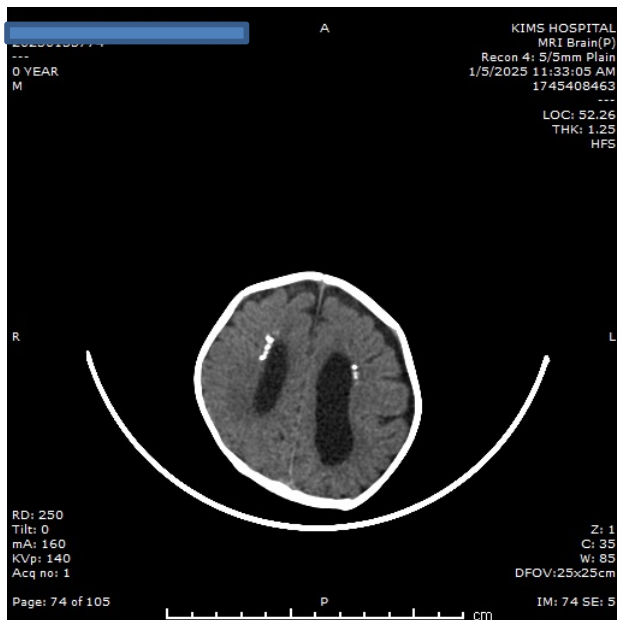
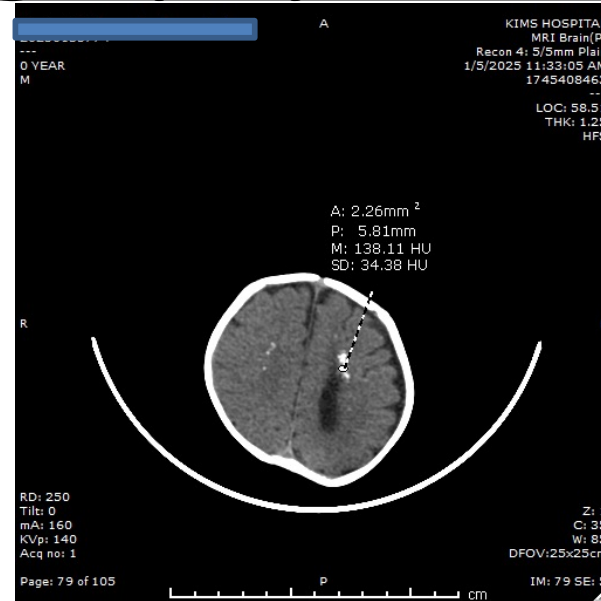
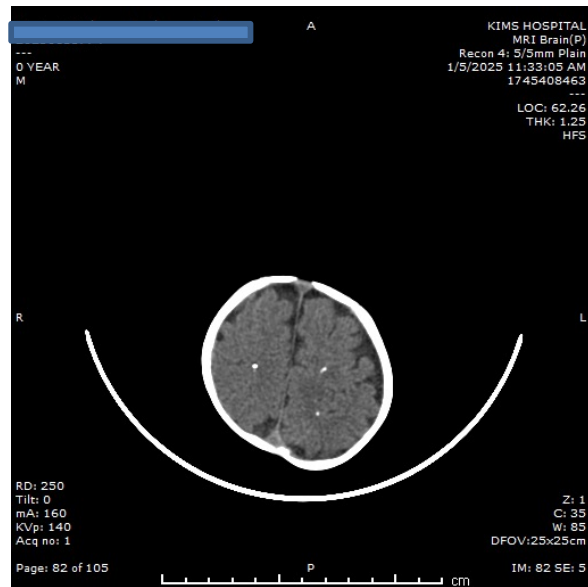
- Birth history :

Single/Term/NVD/Outborn/LBW/CIAB

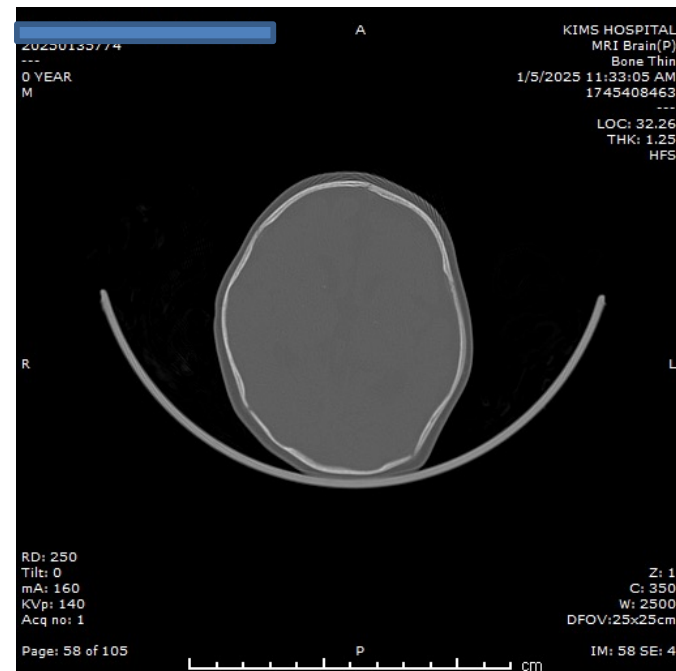
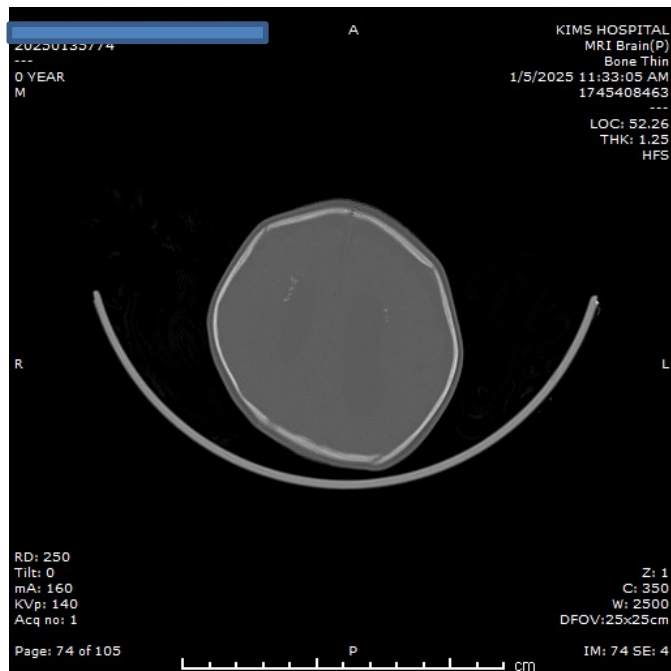
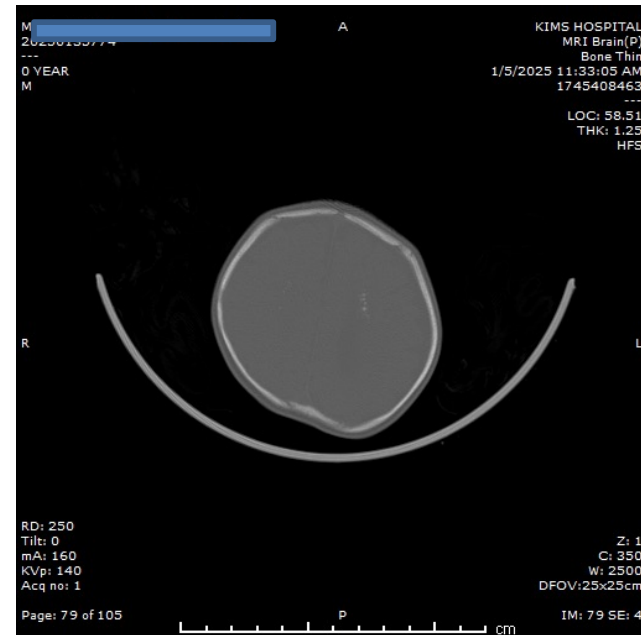
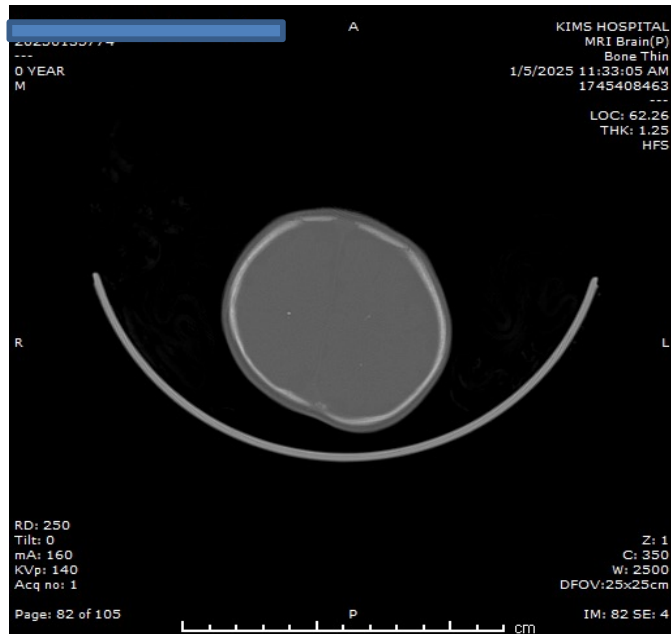
GTCS multiple episodes since birth

ANC history: Mother had fever un 1st trimester
(treated under alternative modality of
treatment)

Computed tomography Brain(plain)

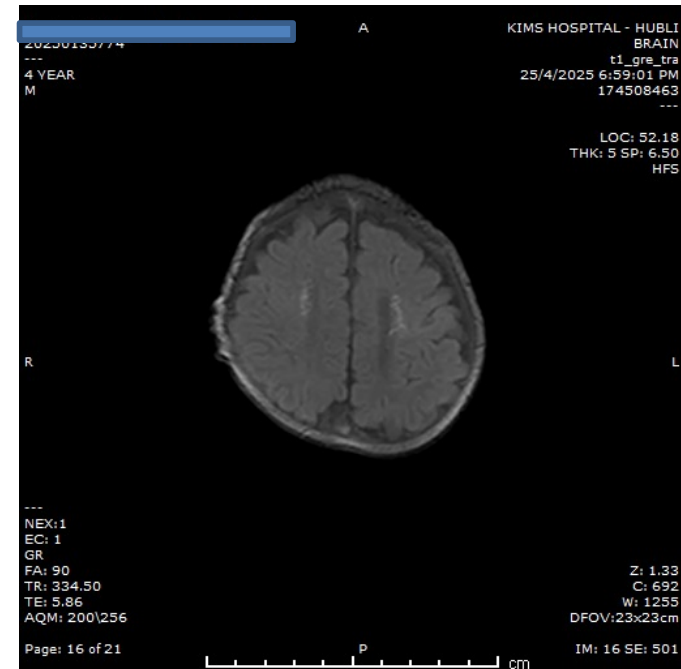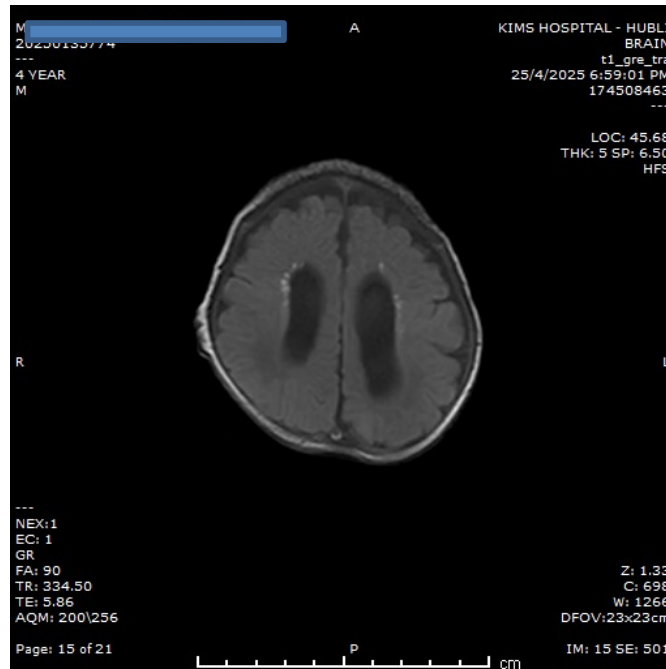


CT-Brain (Bone window)

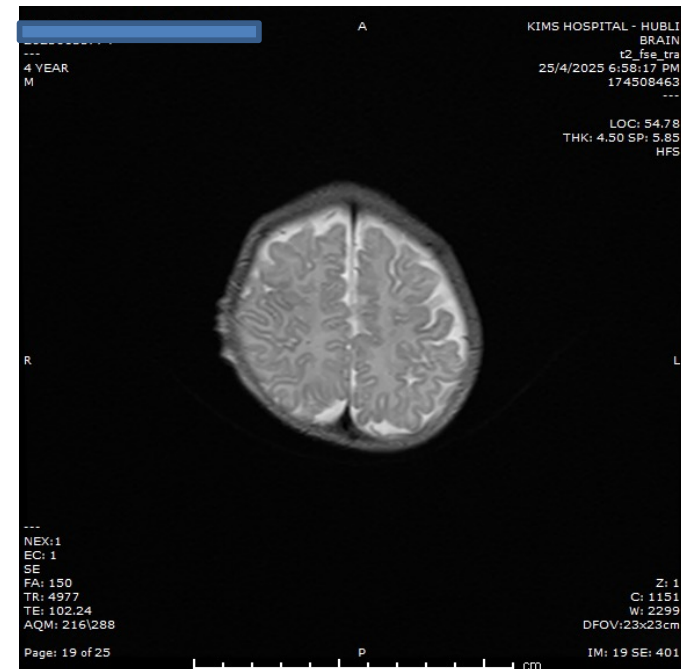
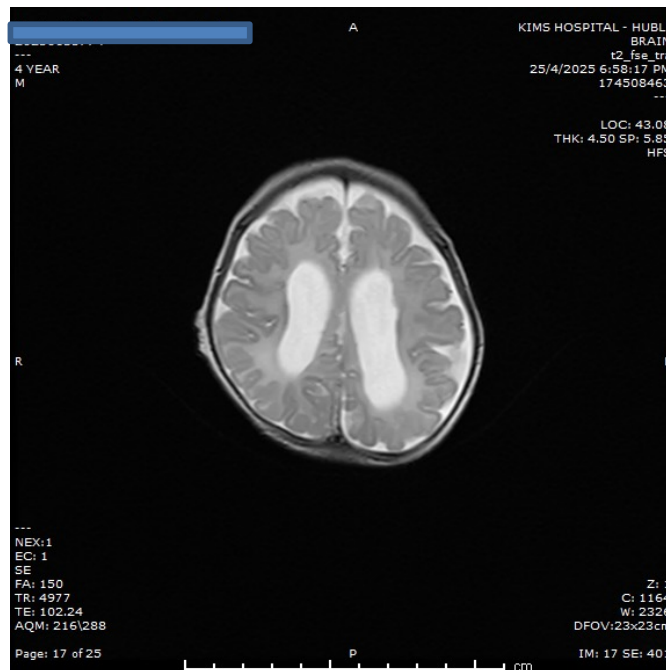


MRI Brain (Plain)

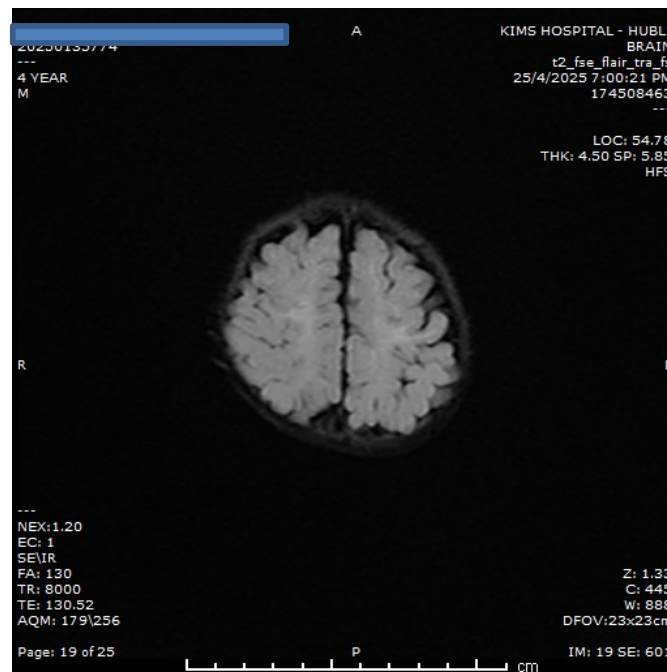
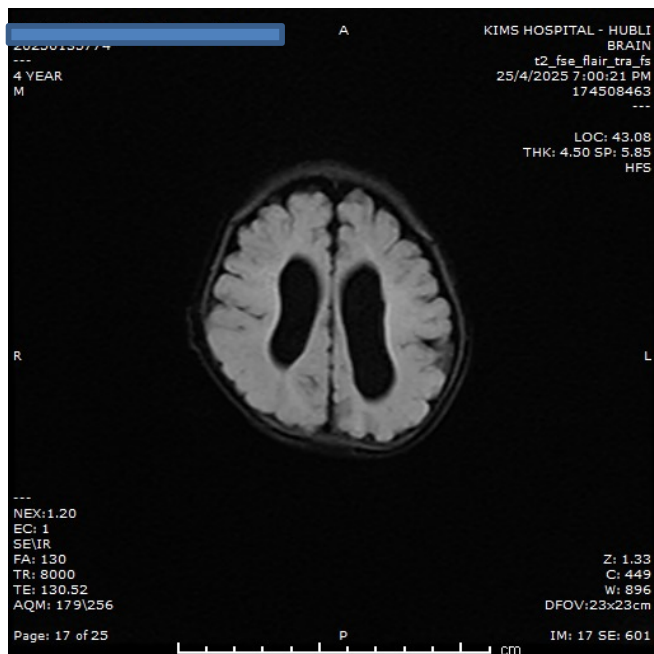
T1-weighted



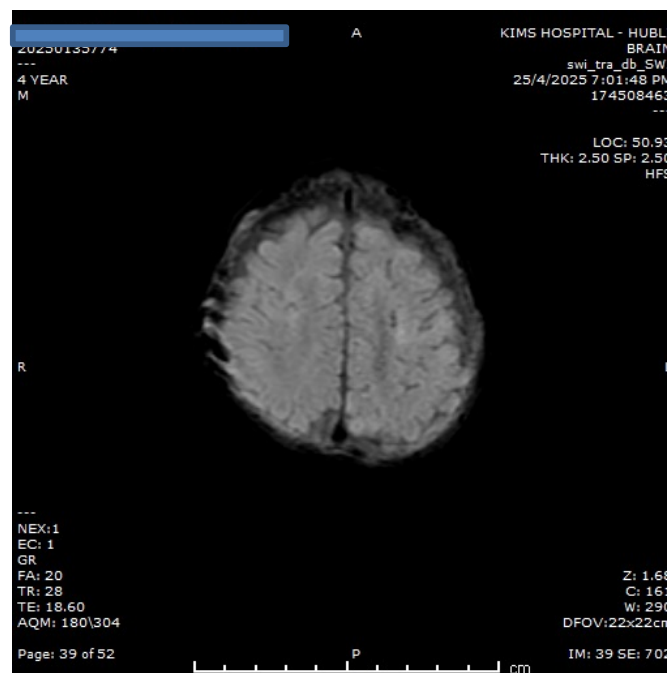
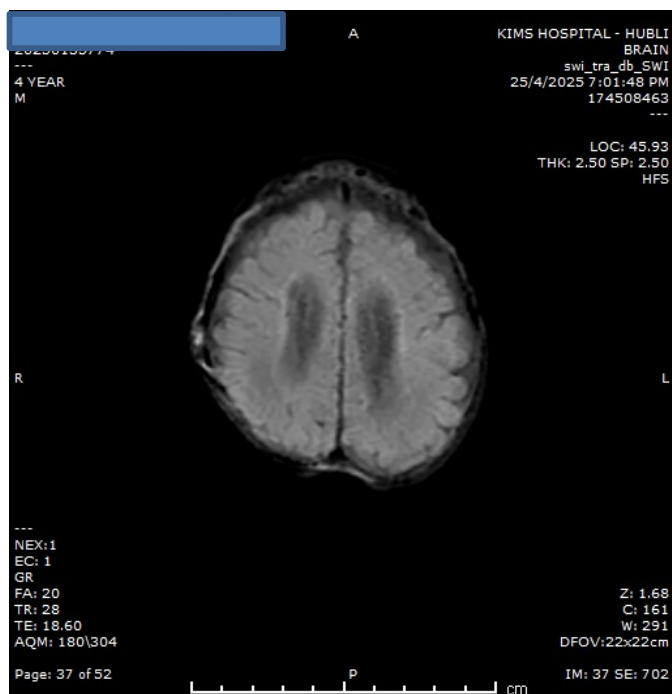
T2-weighted



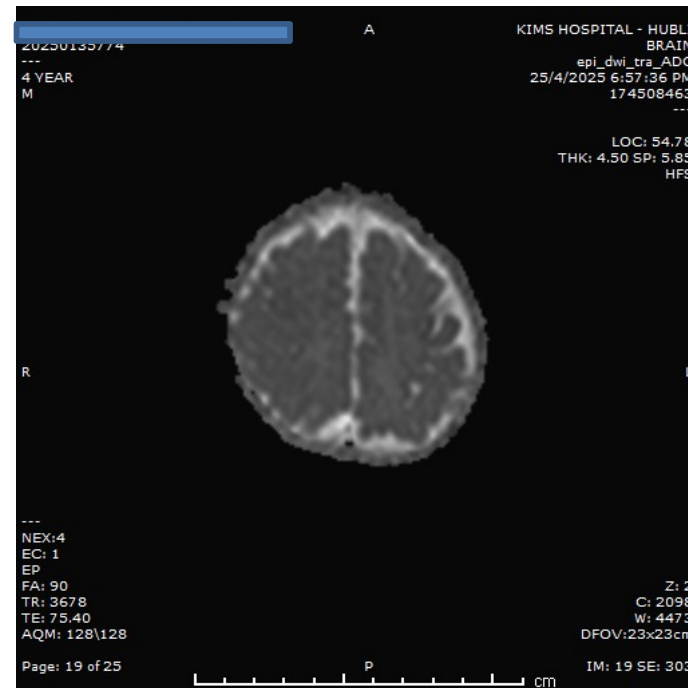
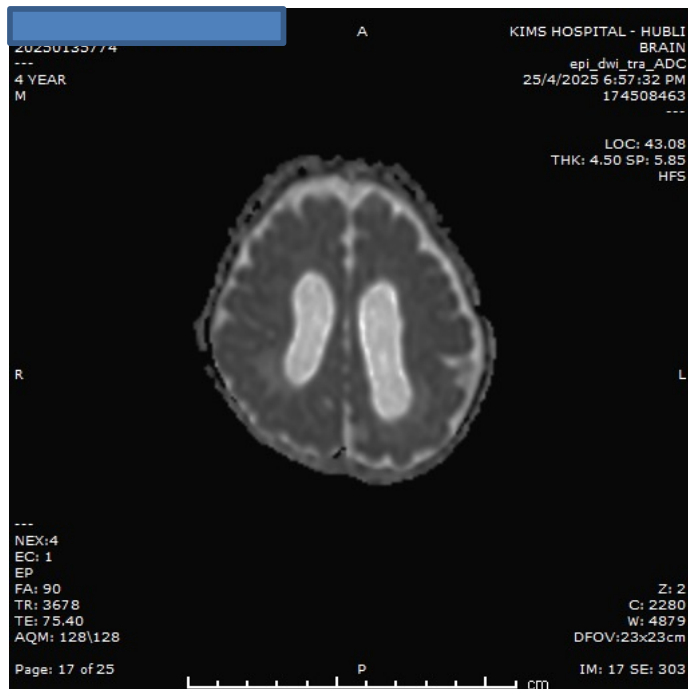
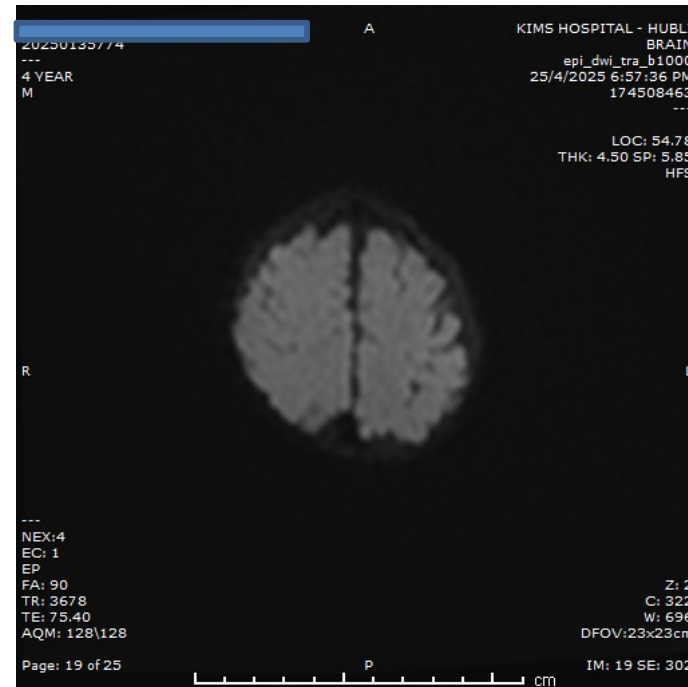
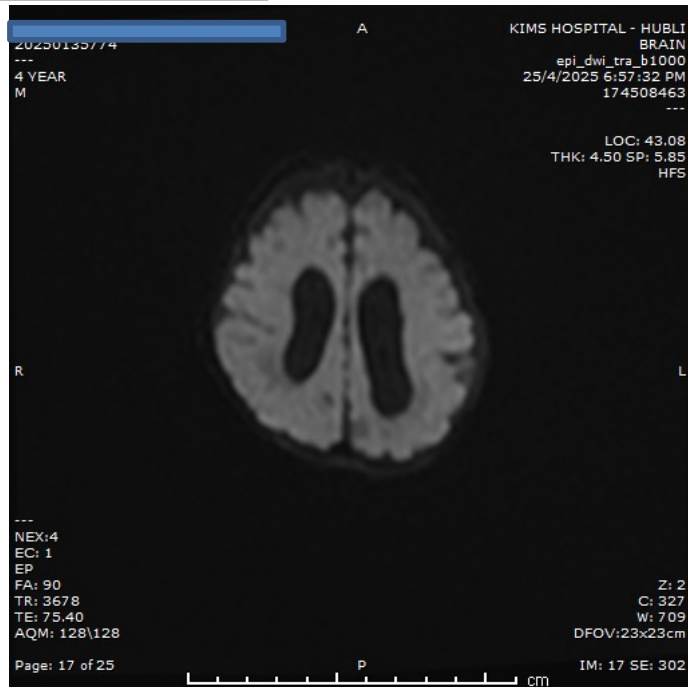
FLAIR



SWI



DWI-ADC



**NODULAR CALCIFICATION IN PERIVENTRICULAR REGION, DEEP WHITE MATTER
WITH DILATED BILATERAL LATERAL AND 3RD VENTRICLE FEATURES LIKELY
SUGGESTIVE OF CONGENITAL INFECTION—LIKELY TORCH.**

