



KARNATAKA RADIOLOGY EDUCATION PROGRAM

CASE PRESENTATION

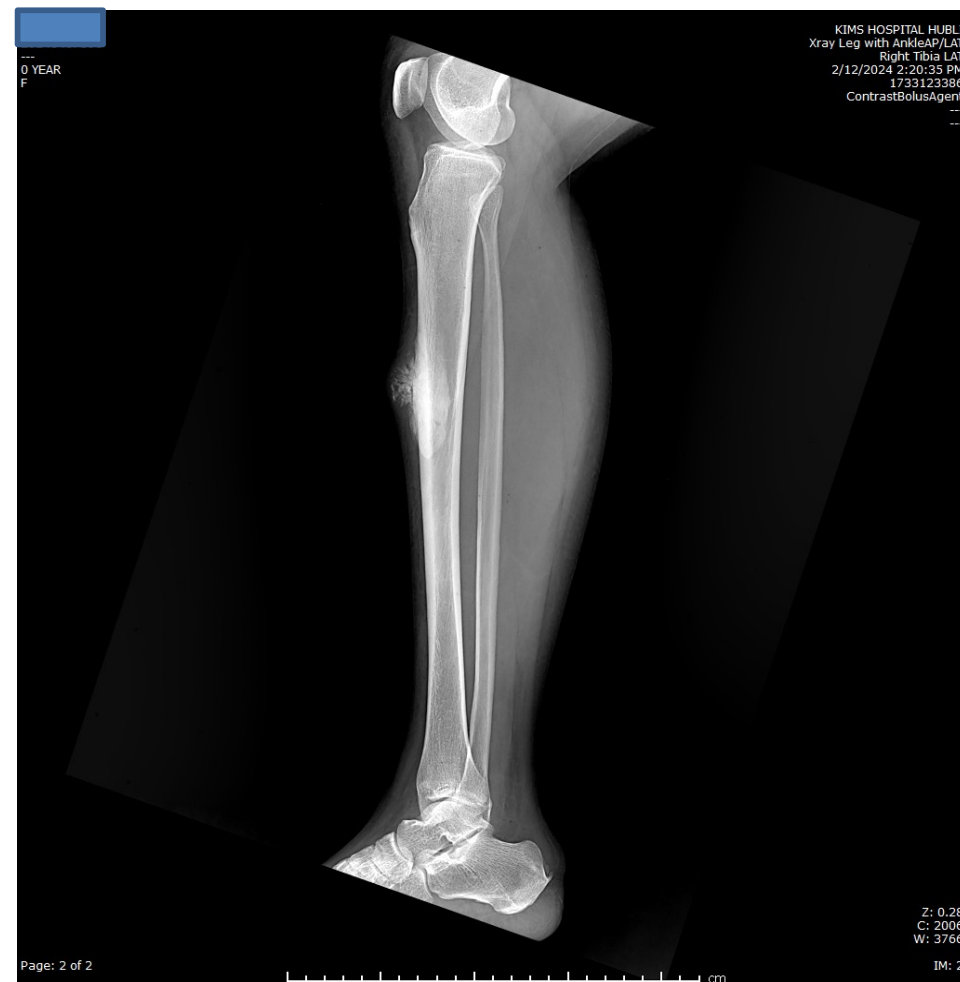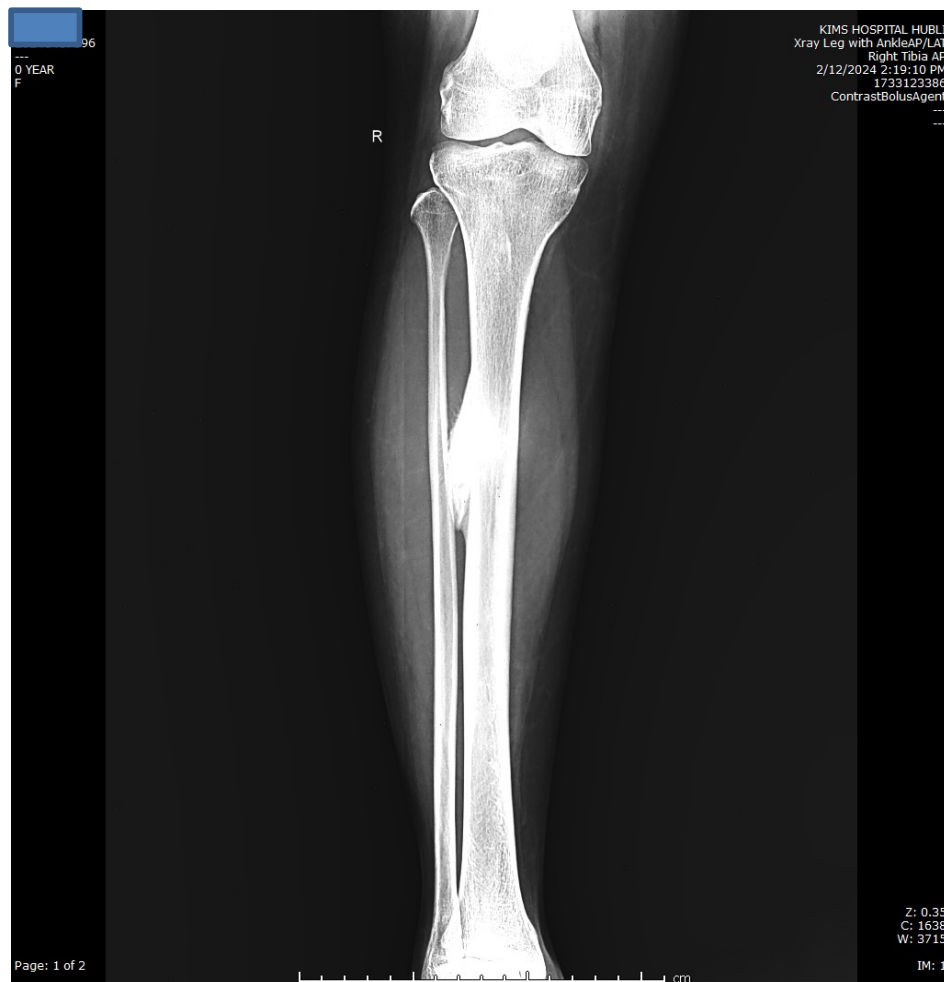
MENTOR: DR G C PATIL

Professor Department of Radiology
KMCRI, HUBBALLI.

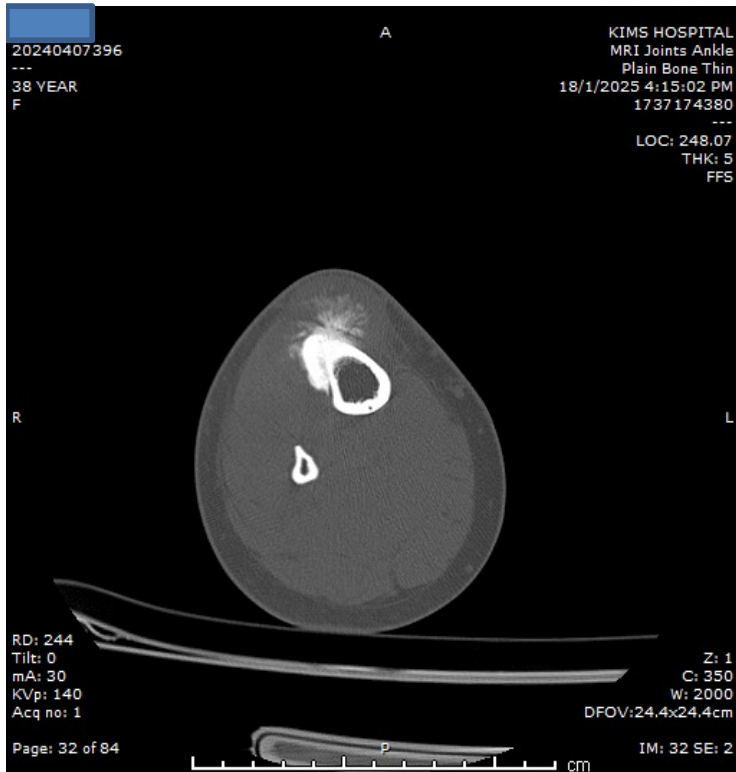
Chief complaint :

- Right leg pain - 4 months
- Swelling in lateral aspect of leg -3 months
- No fever
- No hypertension/diabetes mellitus/ thyroid disorder

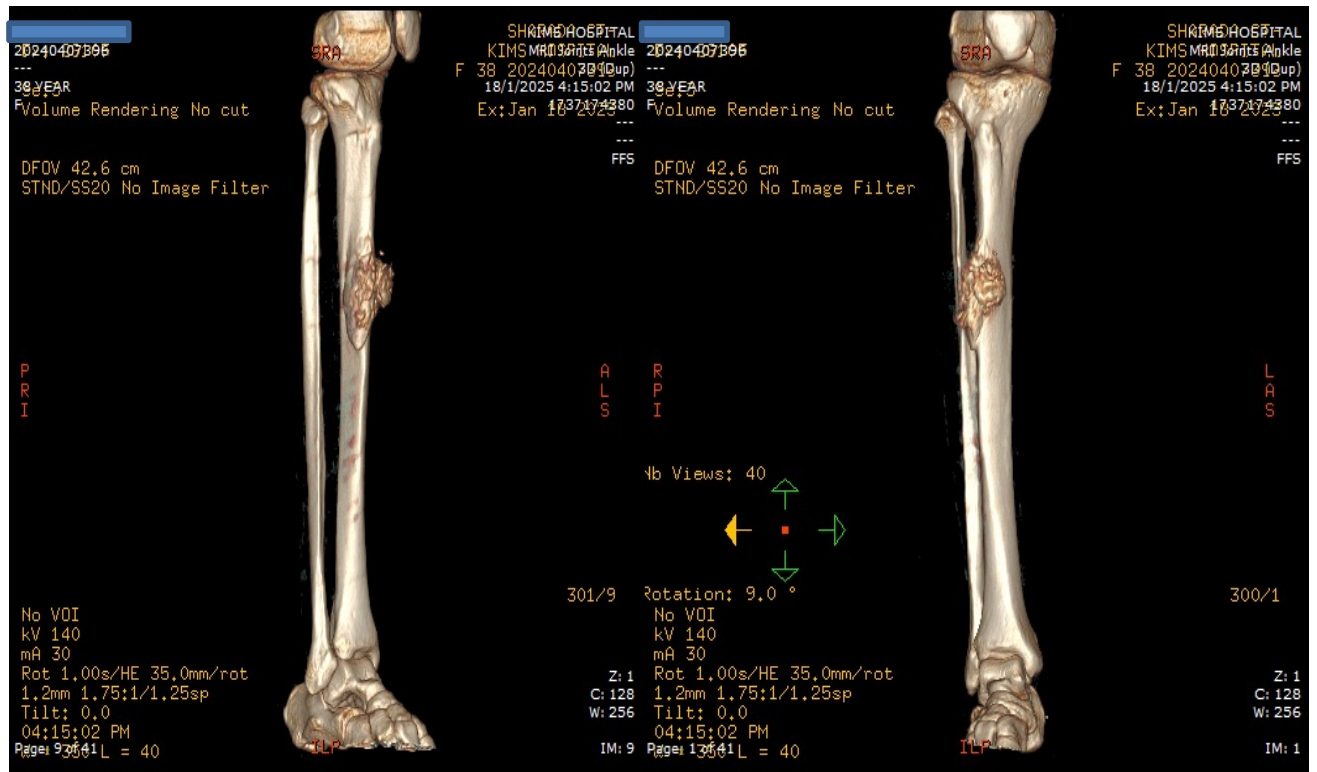
RADIOGRAPH



COMPUTED TOMOGRAPHY

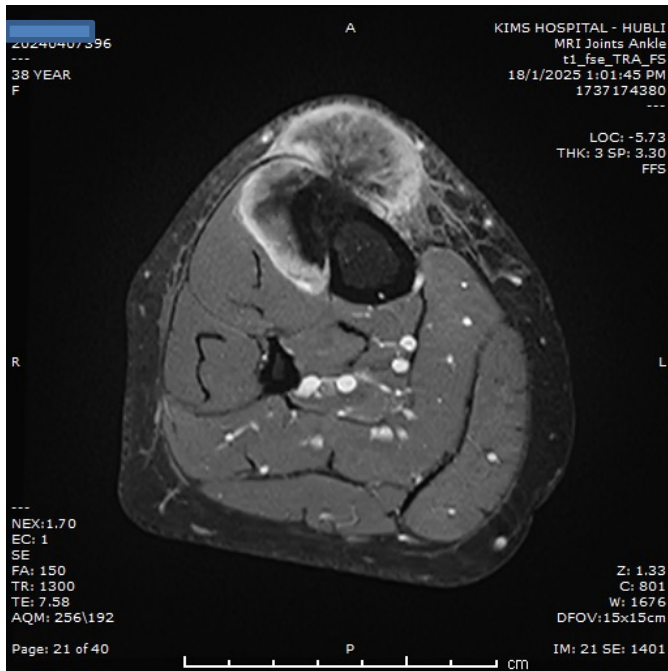


CT AXIAL

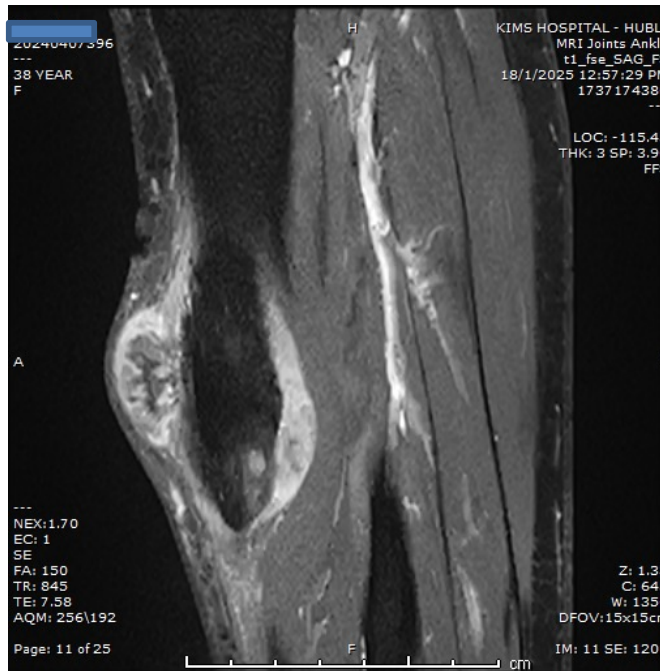


3D RECONSTRUCTION

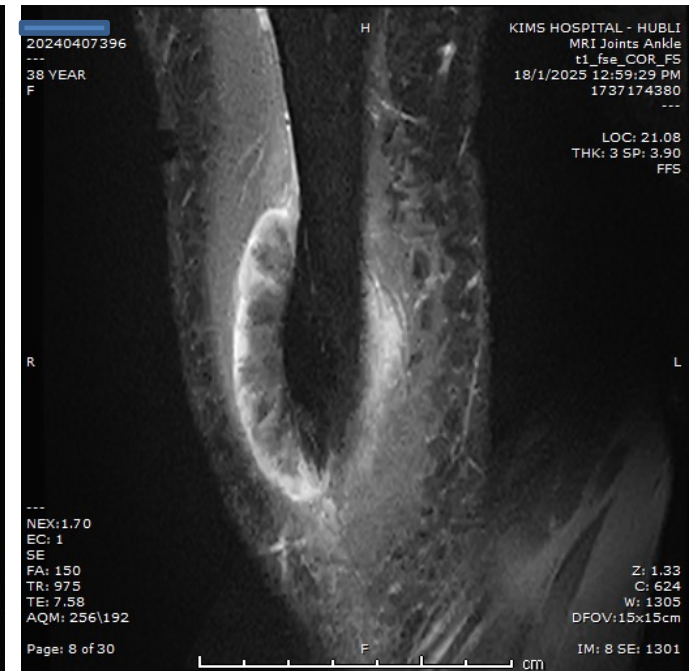MRI



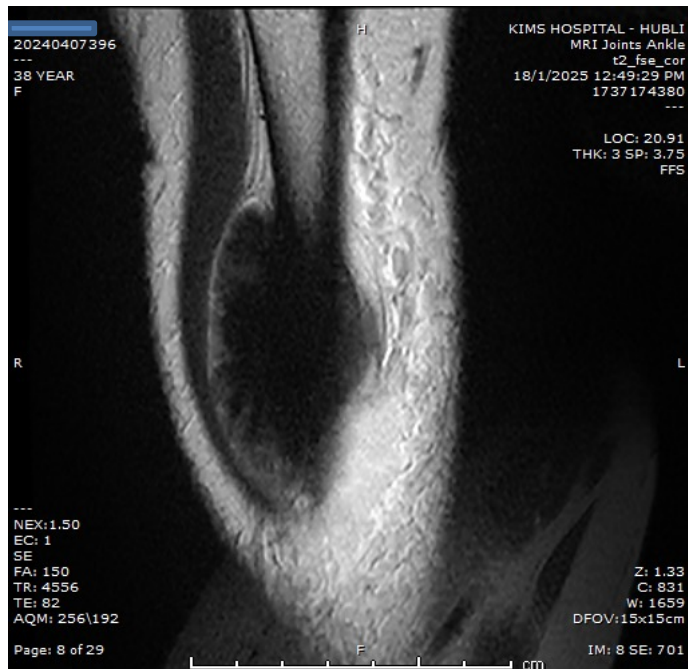
T1 AXIAL FS



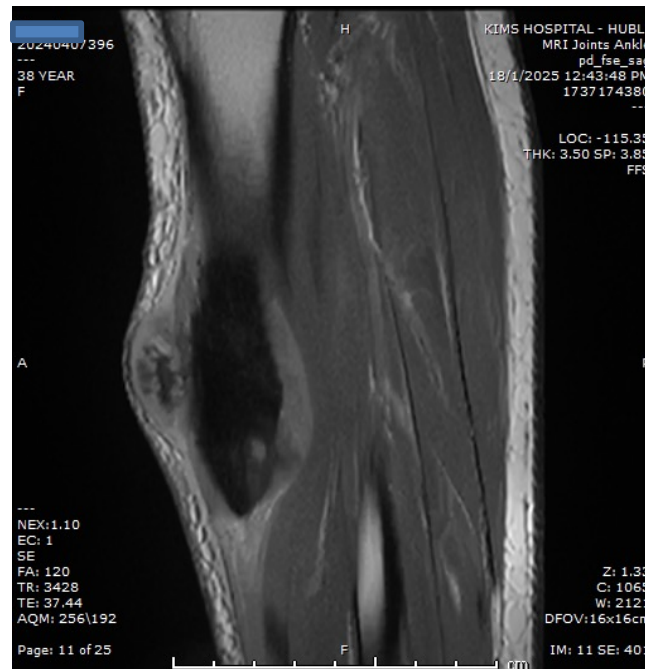T1 SAGITTAL FS



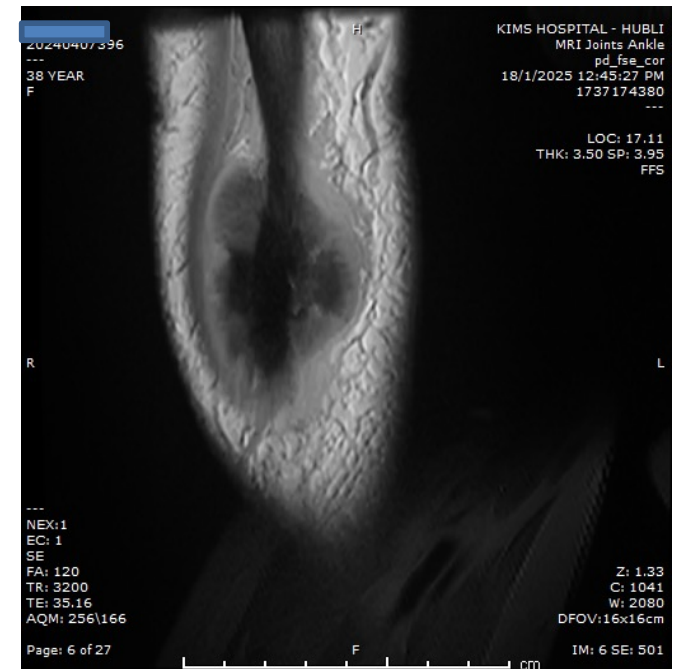
T1 CORONAL FS



T2 CORONAL



PD FSE SAGITTAL



PD FSE CORONAL

HISTOPATHOLOGY

FEATURES SUGGESTIVE OF **OSTEOSARCOMA**

