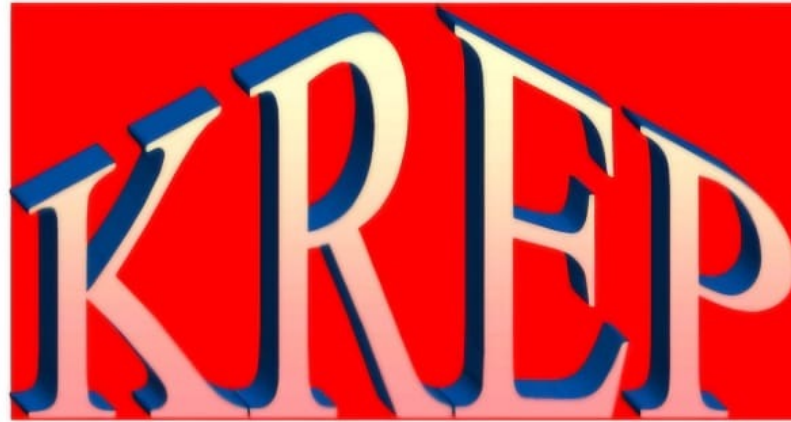



2025

**KARNATAKA RADIOLOGY EDUCATION PROGRAM**

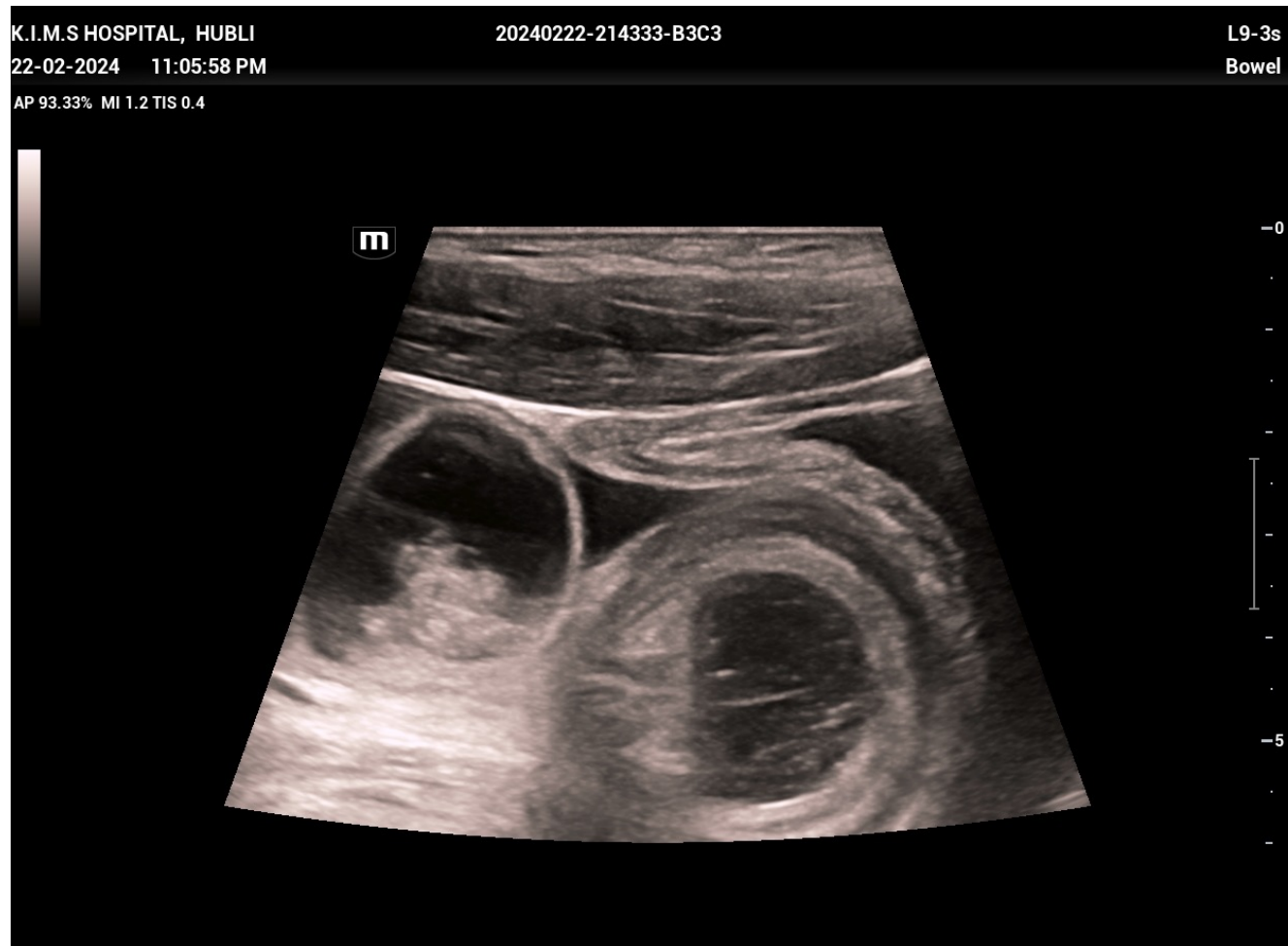# CASE OF INTUSSUSCEPTION

- FROM - Department of Radiodiagnosis , KMCRI Hubli
- MENTOR - DR G C PATIL , Professor , Department of Radiodiagnosis , KMCRI Hubli

# HISTORY AND EXAMINATION

- NAME - Rafik
- AGE / SEX - 25 years / Male
- CHIEF COMPLAINTS - pain abdomen , nausea , vomiting , loose stools since 2 days
- EXAMINATION- diffuse abdominal tenderness, guarding present , hyperperistaltic bowel sounds.
- No significant past history

# USG FINDINGS

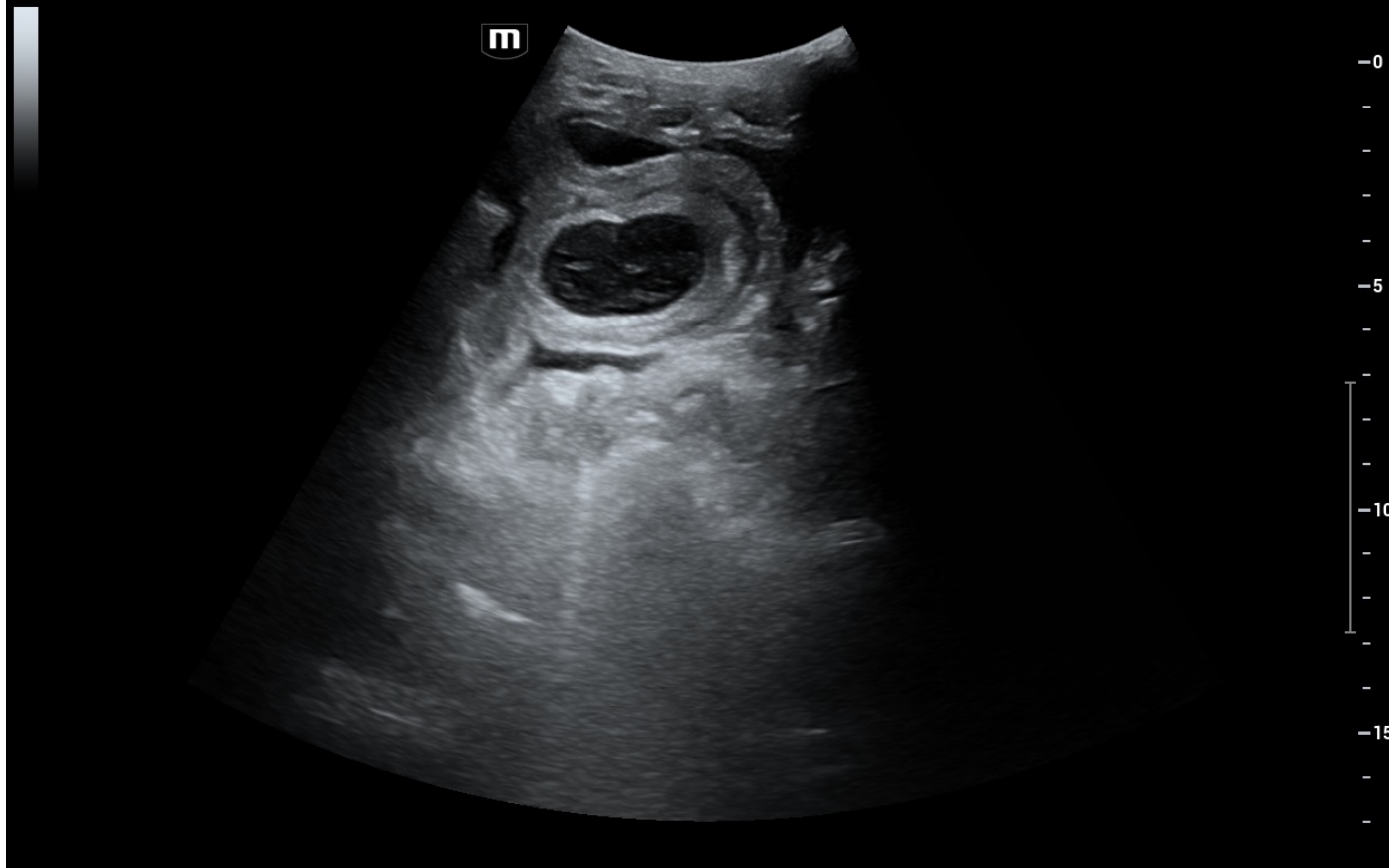


K.I.M.S HOSPITAL, HUBLI  
22-02-2024 11:06:38 PM

20240222-214333-B3C3

SC6-1s  
Adult ABD

AP 93.33% MI 1.2 TIS 0.7



K.I.M.S HOSPITAL, HUBLI

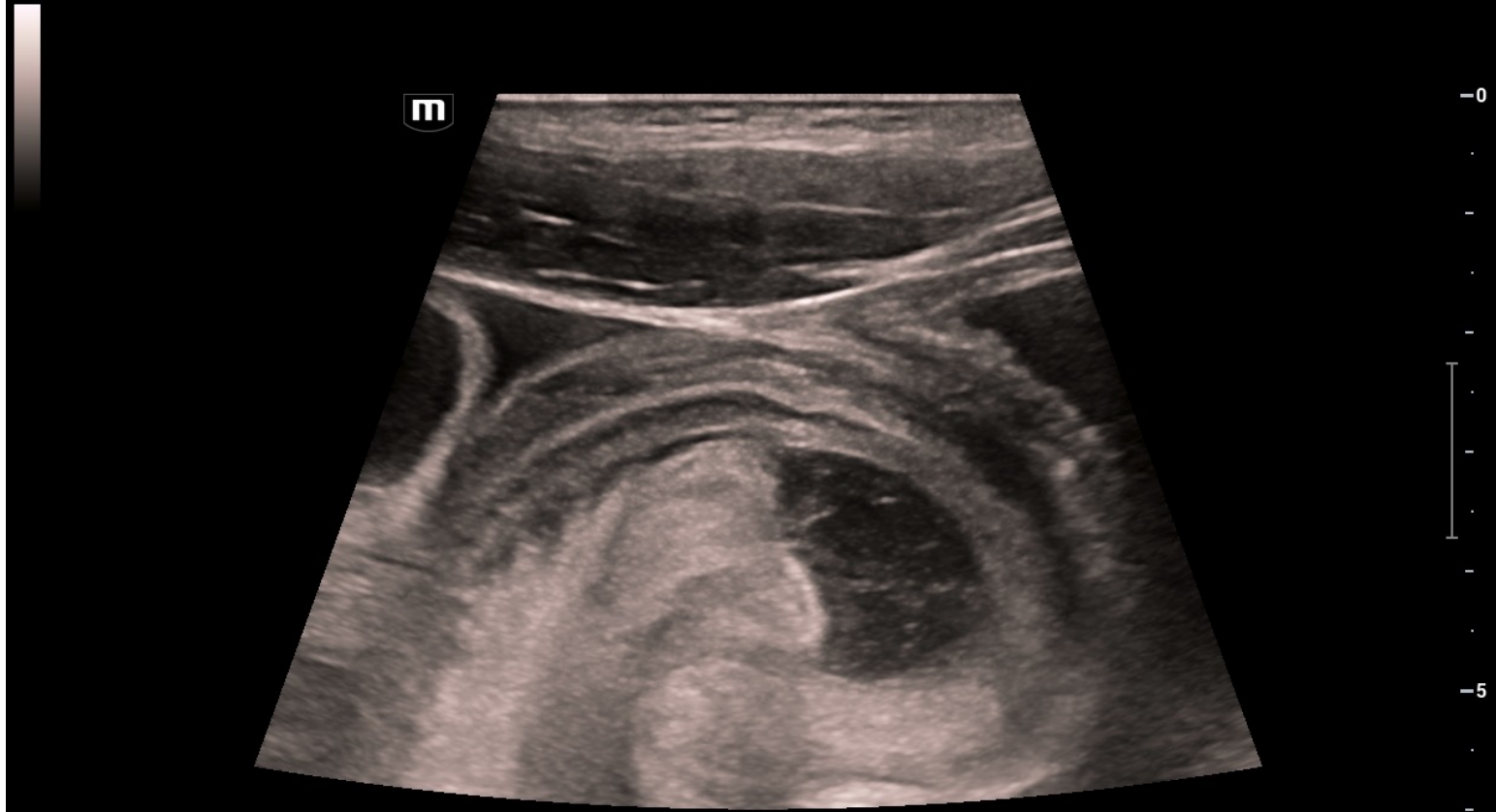
20240222-214333-B3C3

L9-3s

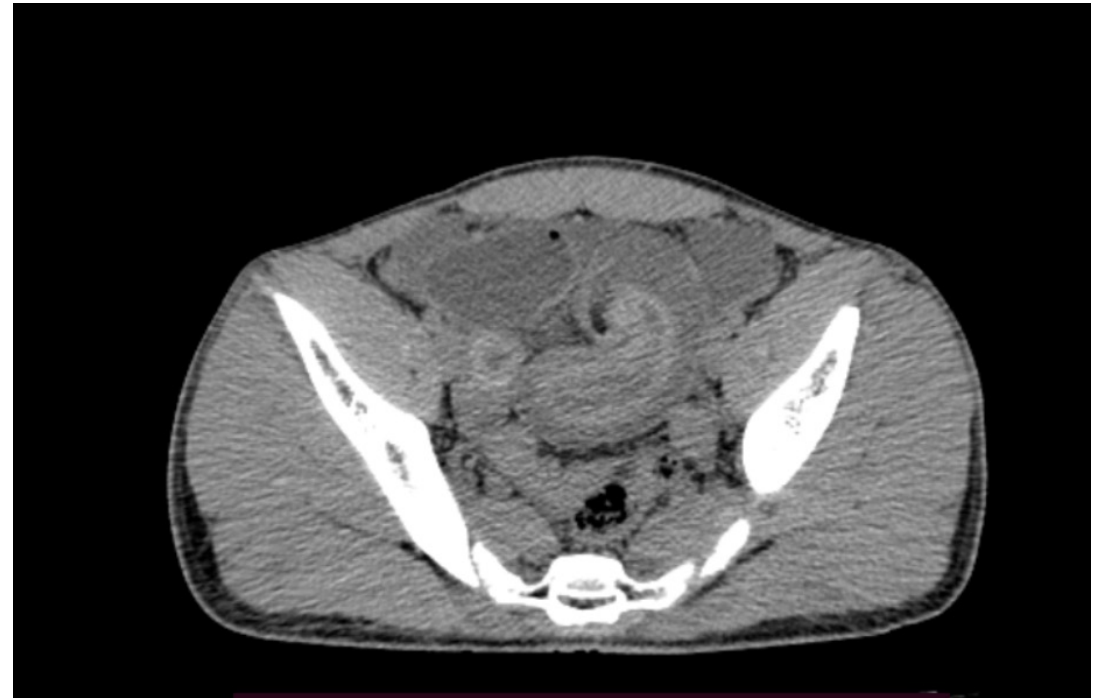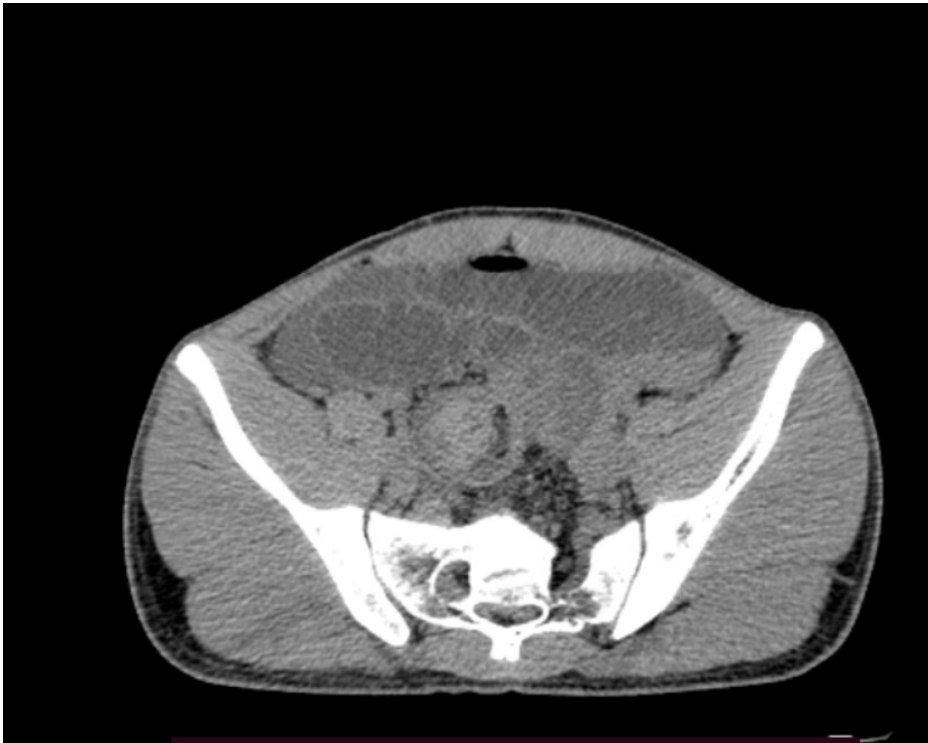
22-02-2024 11:06:14 PM

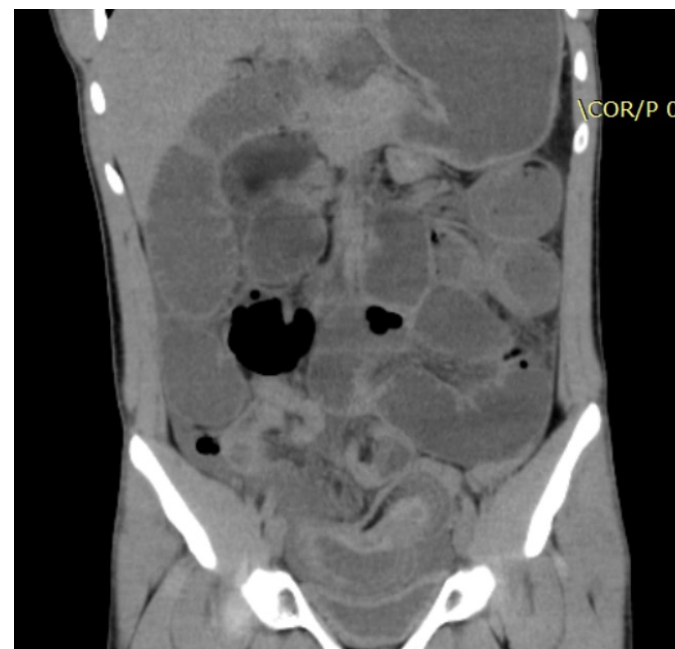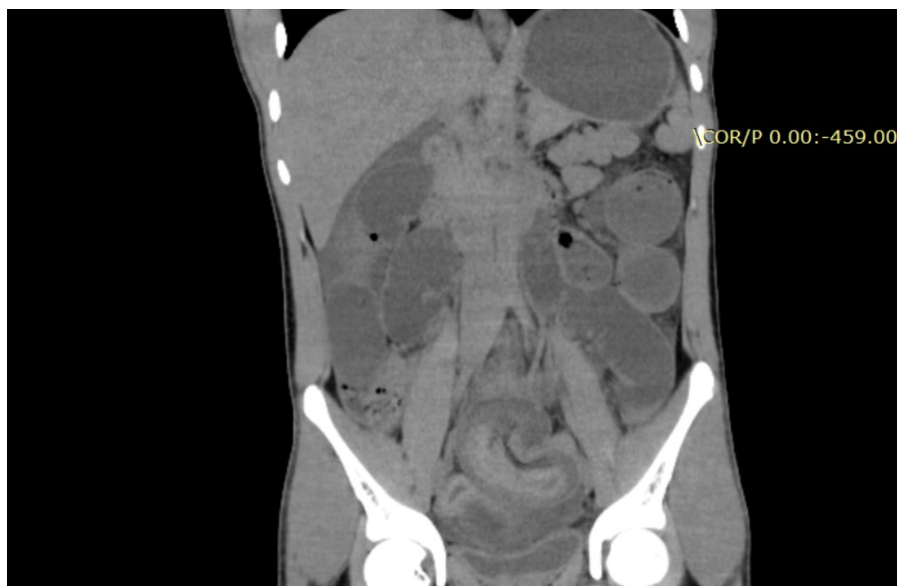Bowel

AP 93.33% MI 1.2 TIS 0.4



# PLAIN CT ABDOMEN AND PELVIS

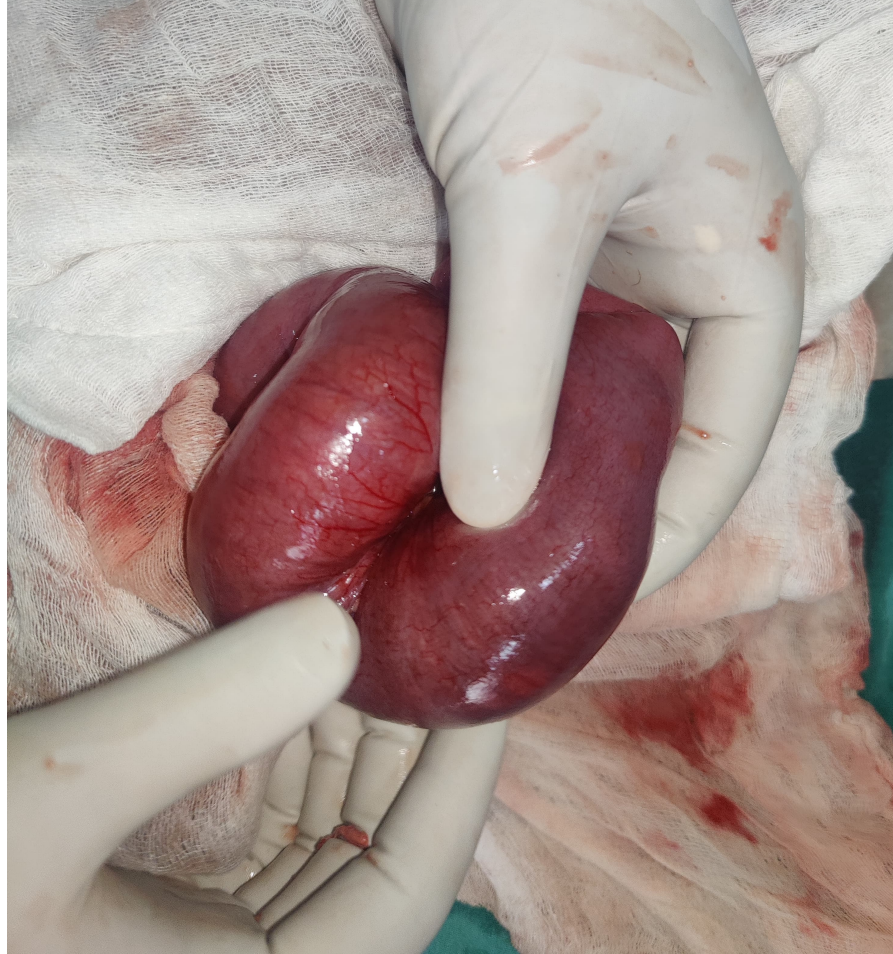





# Imaging findings

- Invagination of ileal loops into distal segments of the loops noted , no obvious mass/lesion as leading point noted - features suggestive of ileoileal intussusception



- Intraoperatively distal ileoileal intussusception noted , however no obvious mass or lesion as leading point noted

THANK YOU