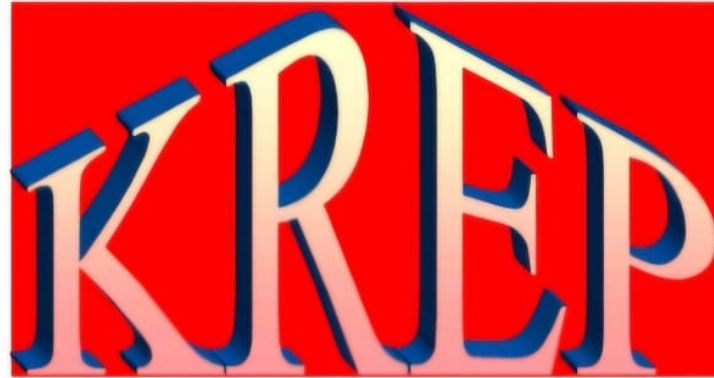



2025

KARNATAKA RADIOLOGY EDUCATION PROGRAM

A CASE OF CSF RHINORRHEA

MENTOR - Dr G C PATIL

KMCRI, Hubli

HISTORY

□ NAME : SANJU

□ AGE : 35 YEARS

□ CHIEF COMPLAINTS:-

ON AND OFF FEVER SINCE 15 DAYS

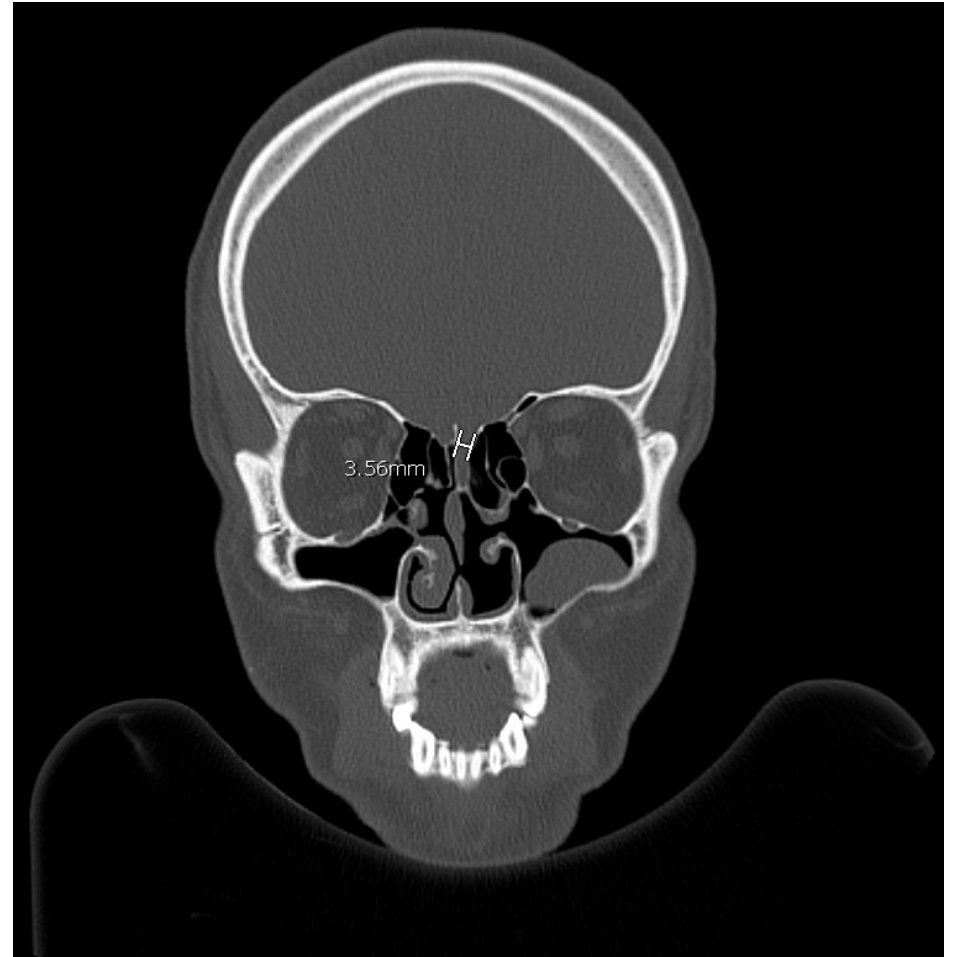
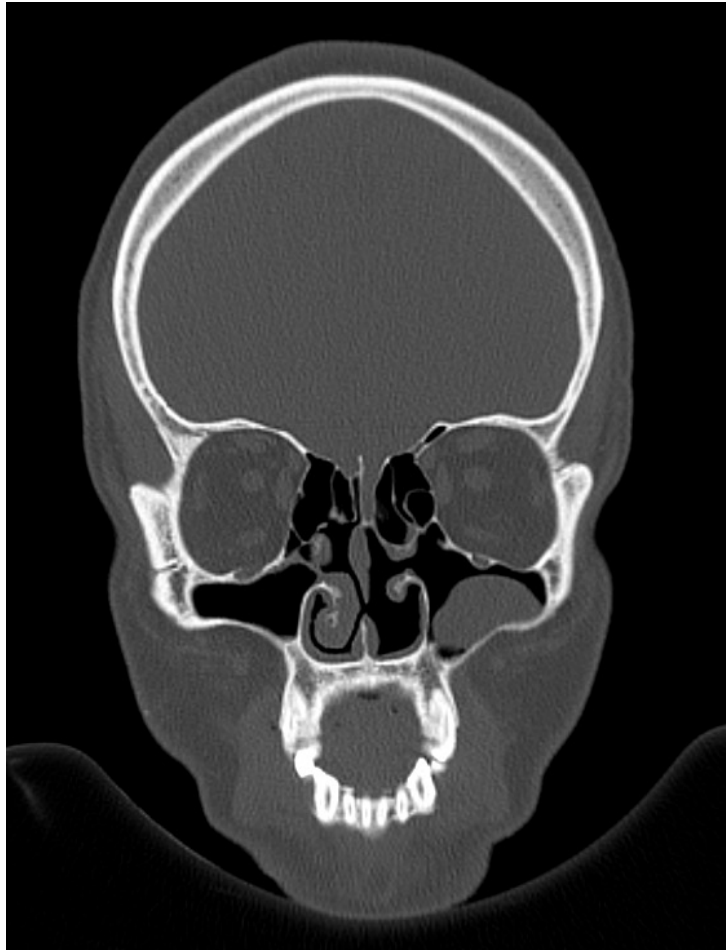
HEADACHE SINCE 15 DAYS

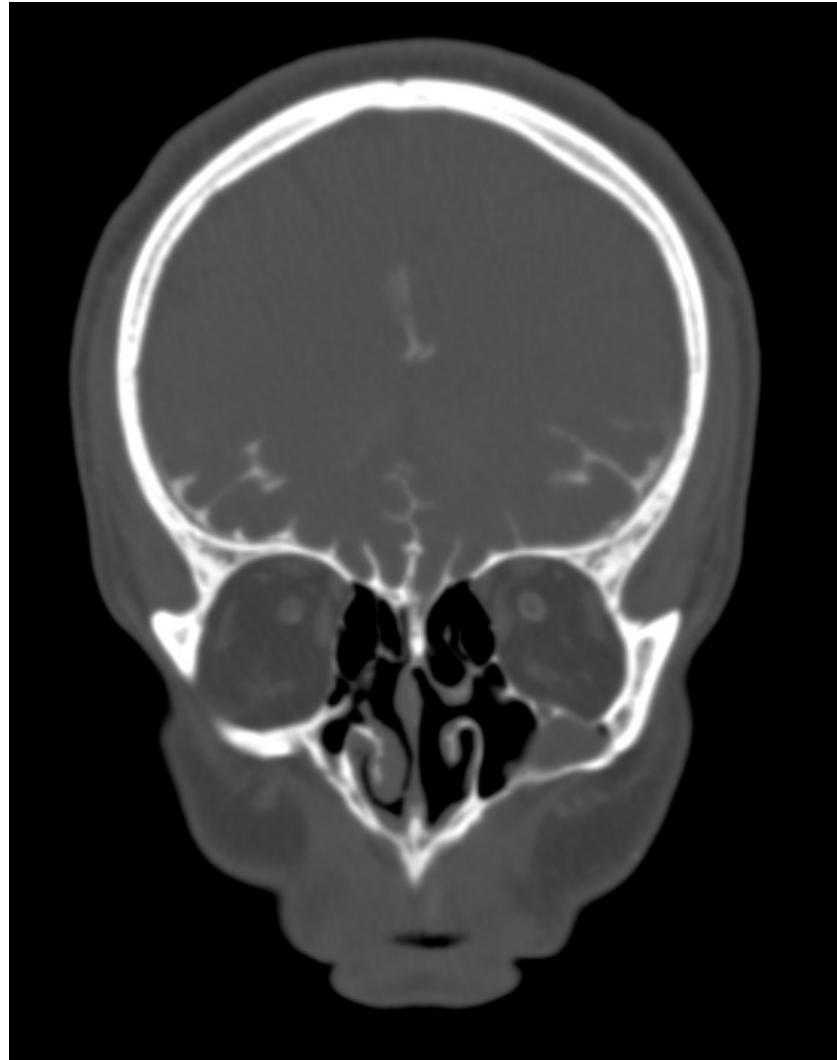NECK RIGIDITY SINCE 10 DAYS

□ PAST HISTORY:- 2 EPISODES OF MENINGITIS SINCE 3 YEARS

UNDERGONE NASAL SURGERY 10 YEARS AGO

□ GOT ADMITTED IN MICU FOR RECURRENT MENINGITIS AND CAME TO KNOW ABOUT HISTORY OF INTERMITTENT CLEAR WATERY DISCHARGE FROM THE RIGHT SIDE OF NASAL CAVITY.





- Defect seen in right cribriform plate measuring 3.5mm noted herniation of meninges with extravasation of contrast opacified CSF through the defect seen in right cribriform plate into the superior nasal cavity s/o CSF rhinorrhea.
- ☐ Polypoidal mucosal thickening seen in right maxillary sinus
- ☐ Mild mucosal thickening seen in left maxillary sinus
- ☐ Mucosal thickening seen in bilateral nasal cavities
- ☐ Hypertrophy of left inferior turbinate seen

THANK YOU

CSF Rhinorrhea

➤ Diverse etiology

Idiopathic

Trauma-Surgical

<1%

Trauma-Nonsurgical

3% of all closed head injuries

30% of skull base fractures

Frontal>Ethmoids>Sphenoids

Inflammatory

Congenital

Neoplasm

SITES OF CSF LEAK

