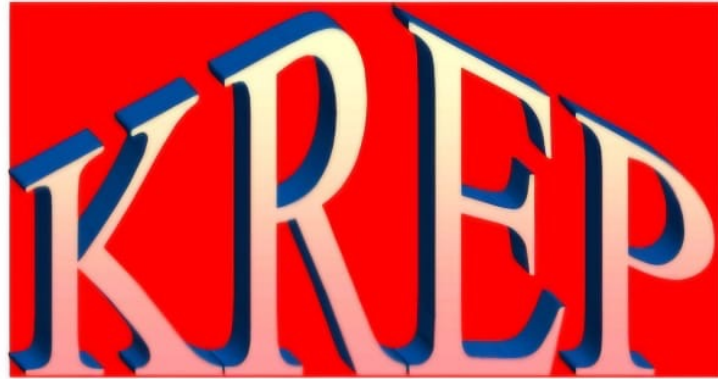



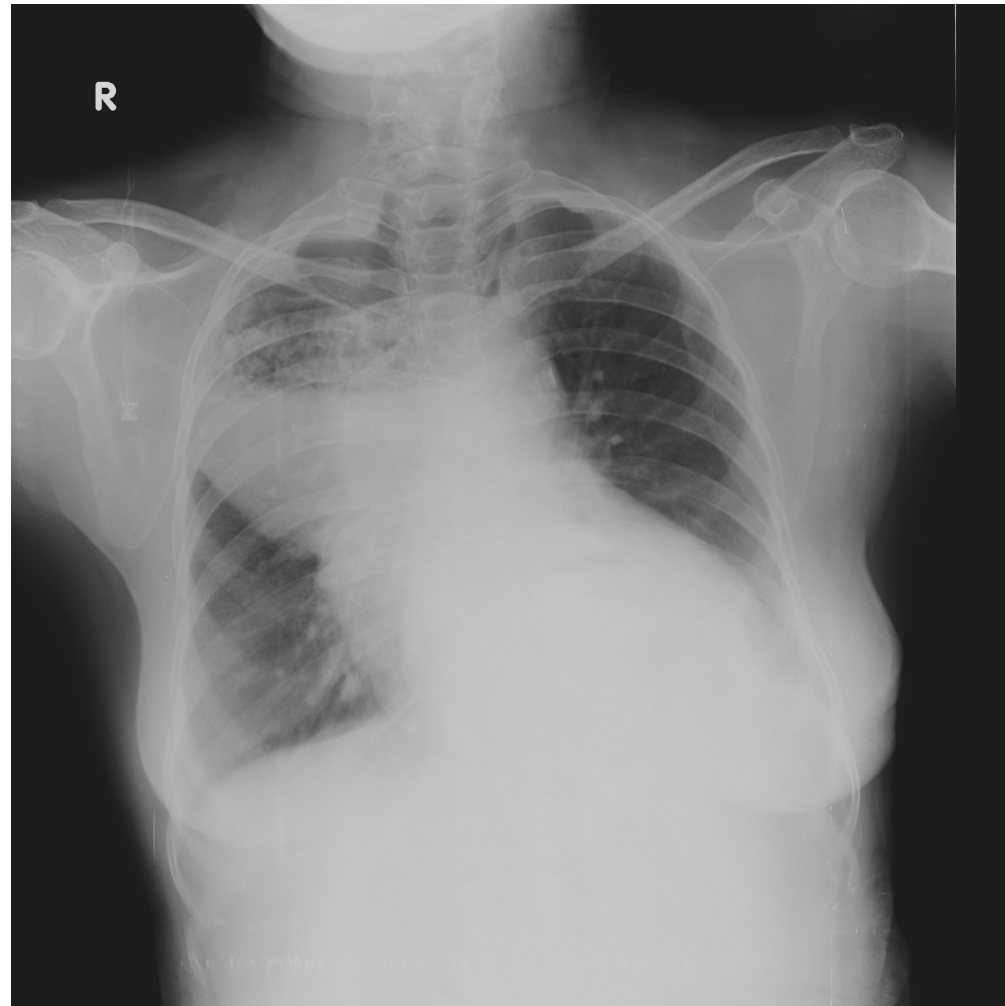
2025

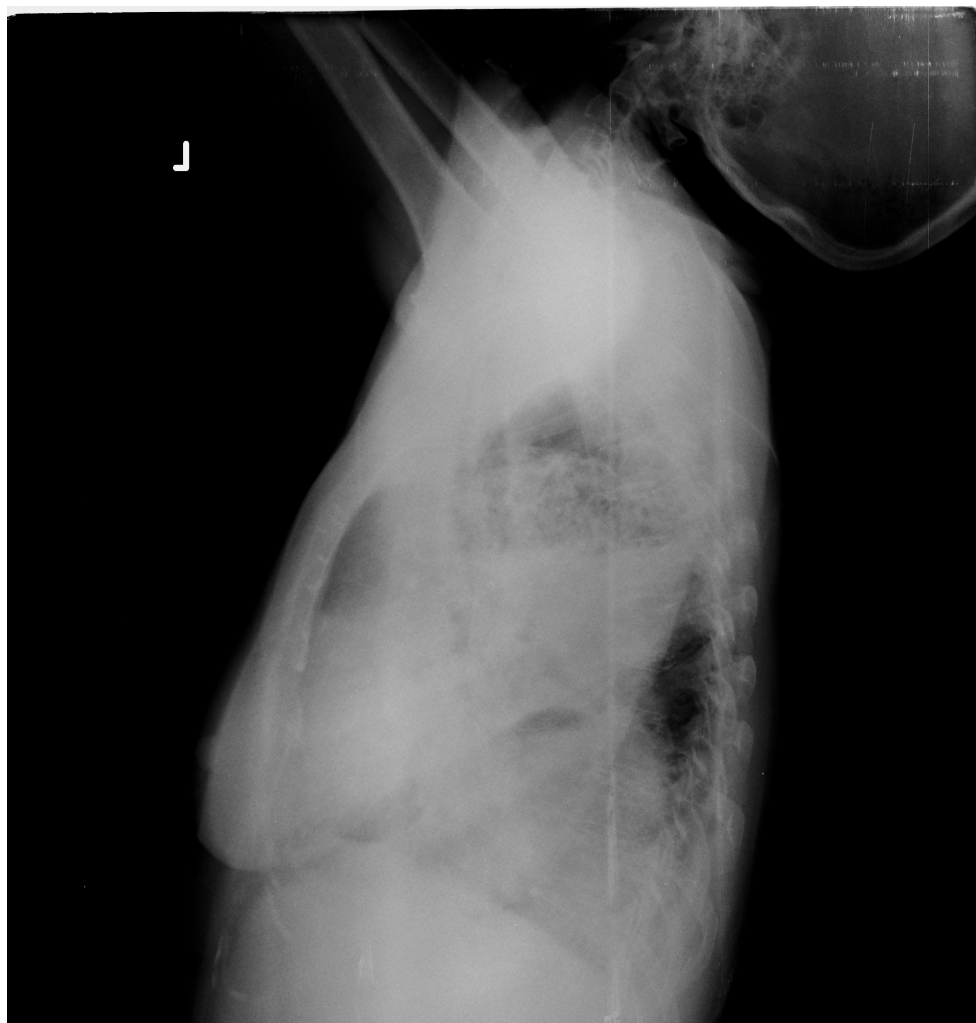
KARNATAKA RADIOLOGY EDUCATION PROGRAM

A CASE OF DYSPHAGIA UNDER EVALUATION

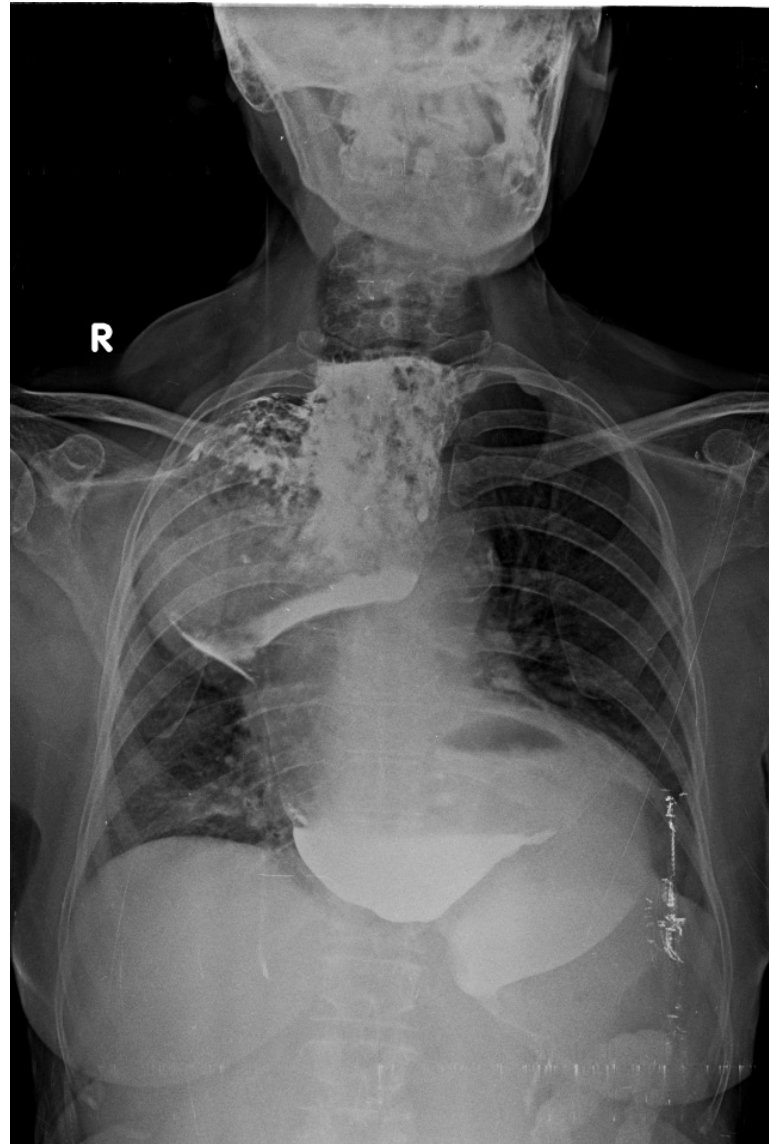
MENTOR - Dr G C PATIL
KMCRI, Hubli

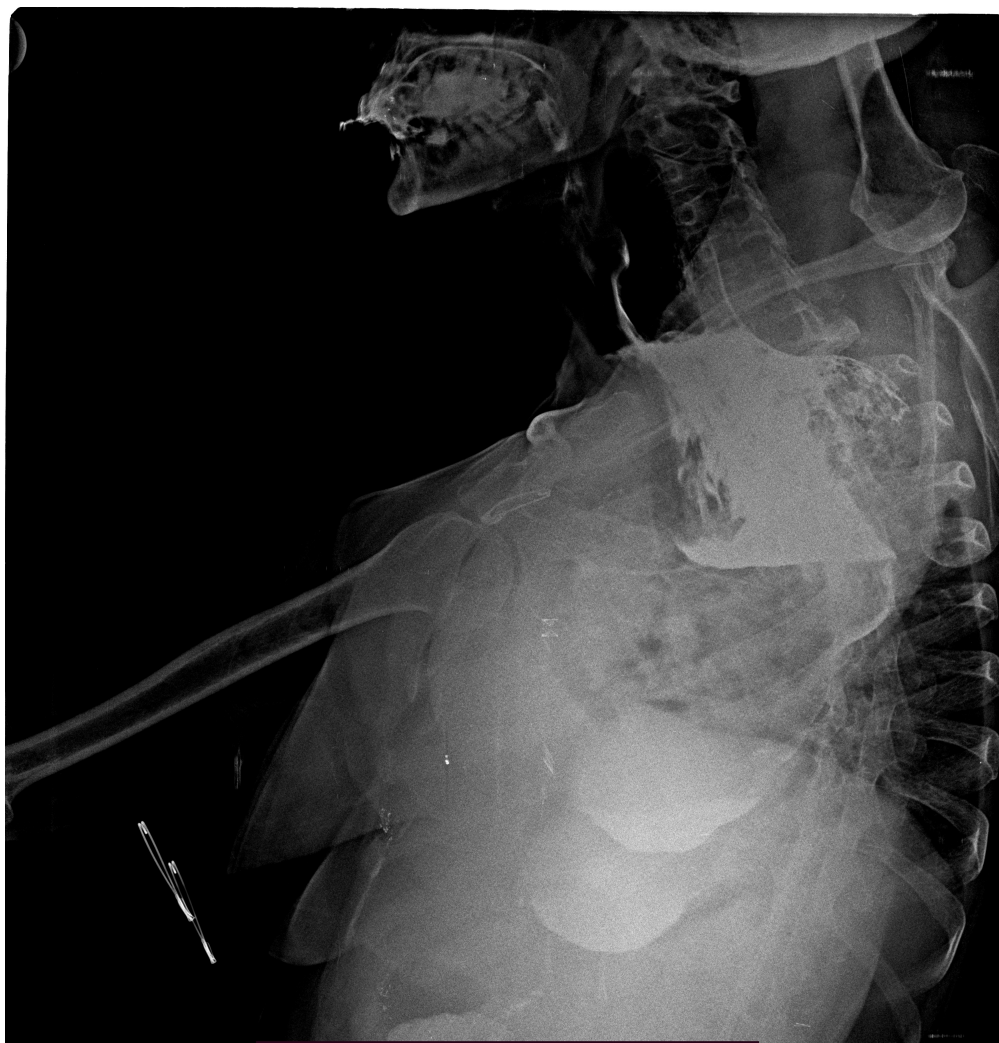
- There is 62 yr old female came with the complaints of
 - Difficulty is swallowing since 10 years
 - Cough since 1 month
 - breathlessness since 1 month
- Past history-
Patient is k/c/o HTN
No history of previous surgery

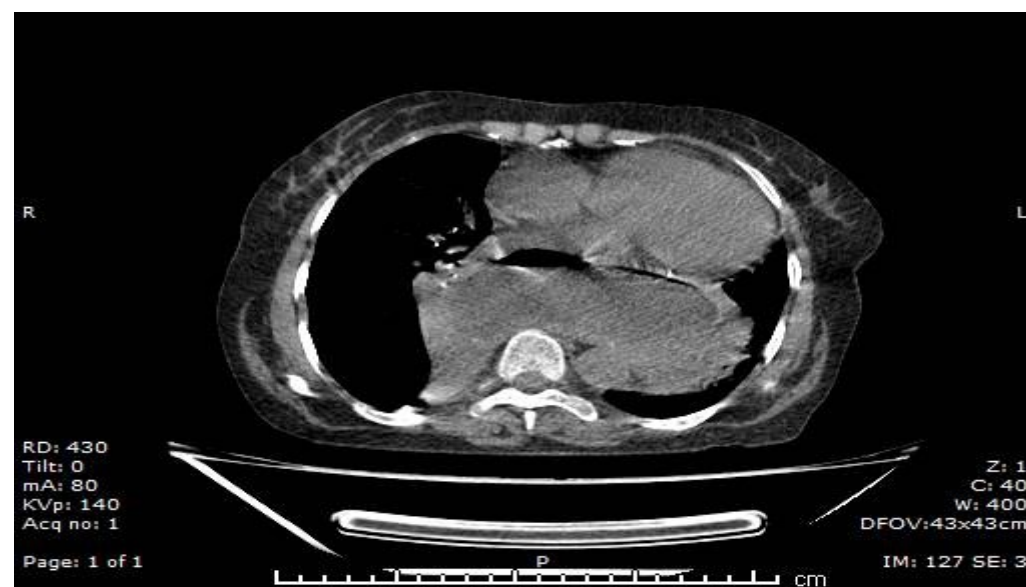
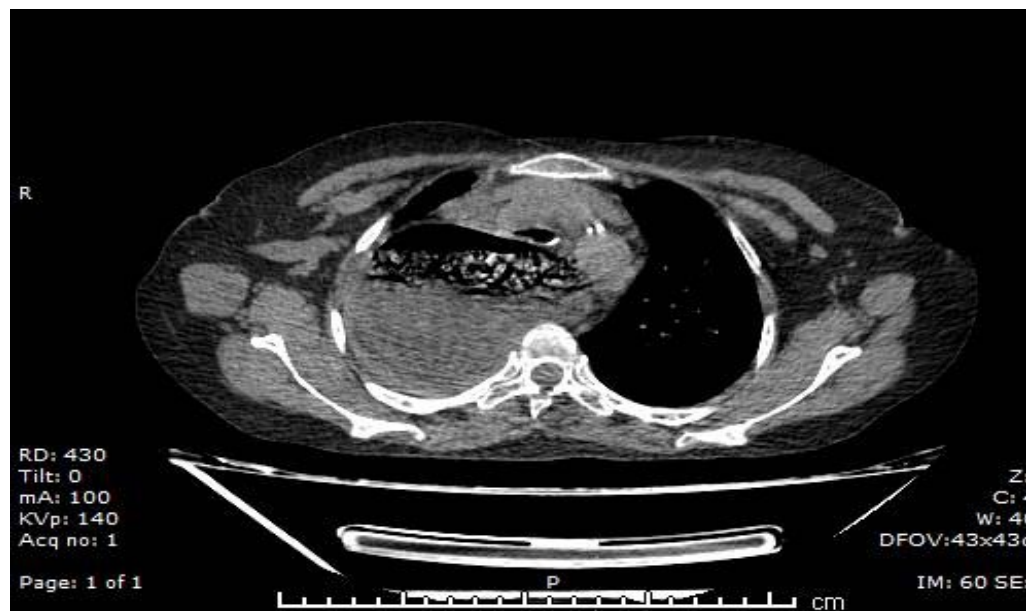


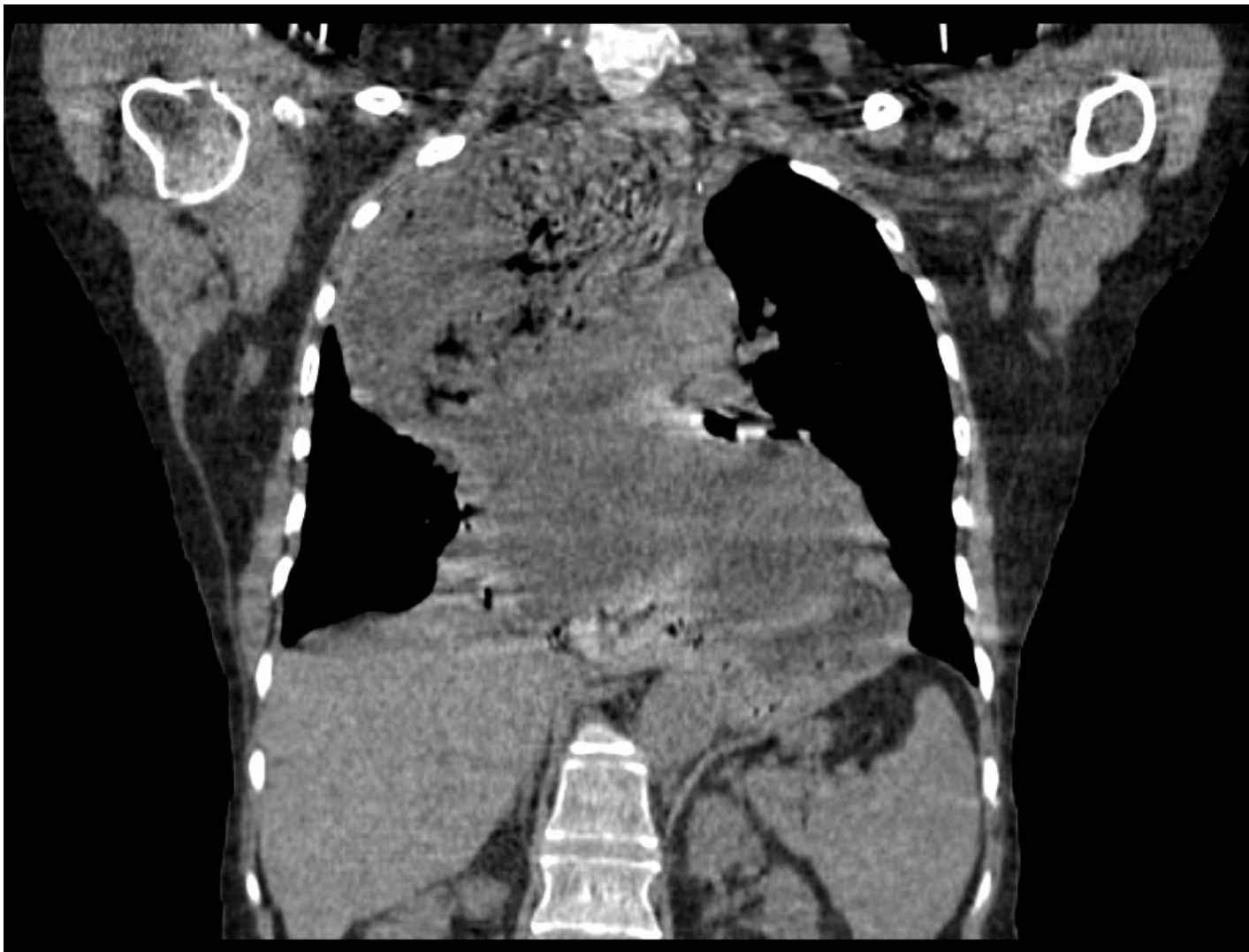
- There is ill-defined heterogenous radioopacity noted in right upper and mid zone with widening of mediastinum involving middle and posterior mediastinum
- DD's:-
 - Achalasia cardia
 - Large hiatal hernia
 - Esophageal duplication cyst
 - Mediastinal abscess









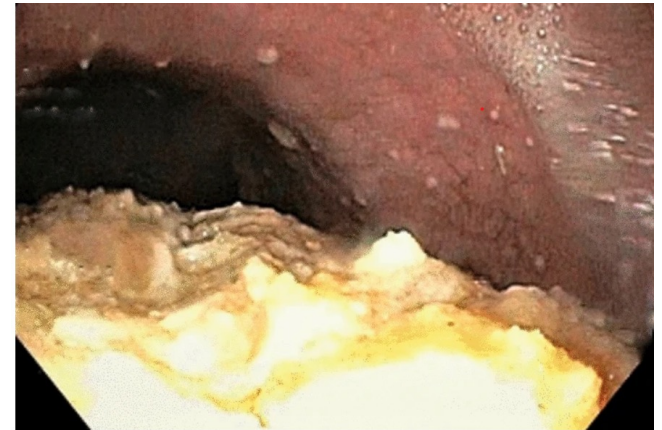
- CT:-

grossly dilated cervical and thoracic oesophagus with smooth tapering at G-E junction with mass effect as described--> f/s/o **Achalasia Cardia**

- Endoscopy:-

Cricopharynx – normal

Esophagus – grossly dilated and filled with food particles





THANK YOU