



KARNATAKA RADIOLOGY EDUCATION PROGRAM

CASE PRESENTATION

MENTOR: DR G C PATIL

Professor Department of Radiology
KMCRI, HUBBALLI.

Chief complaint :

45 year male patient presented with:

- Pain abdomen (diffuse,dull aching,intermittent)- 2 months
- Yellowish discolouration of eyes & hands(Progressive)- 1.5 months
- Vomitting (non-projectile, bilious, Progressive)- 1 month
- Clay coloured stools- 15 days
- Wt loss +
- Decreased appetite+

VITALS:

- BP 92/60 mm of Hg.
- PR:90 bpm.
- RR: 12 cpm.
- SpO2: 98 % at room air

Family history

- **K/C/O : Neurofibromatosis in father & 3 elder brothers (Mother & 2 elder sister: Normal)**

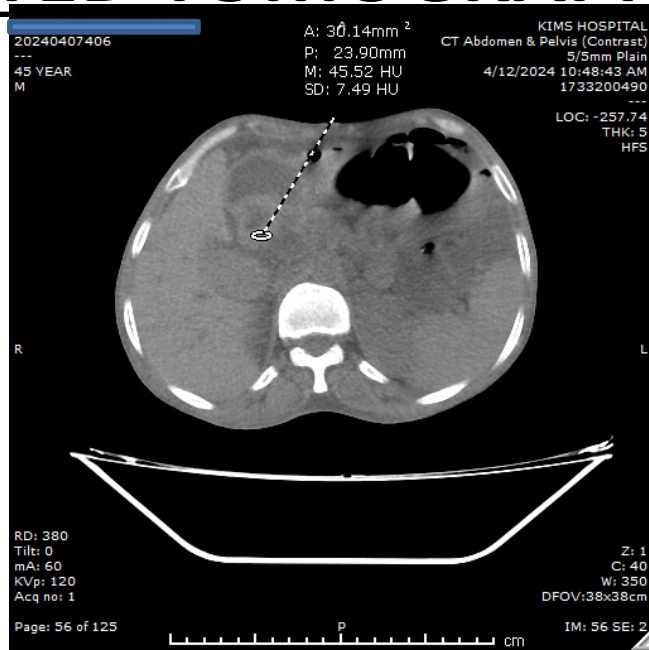
ON EXAMINATION:

Neurofibromatous , multiple small nodule on skin surface over the body. Scar of diagnostic laproscopic noted (KLE -Private hospital)

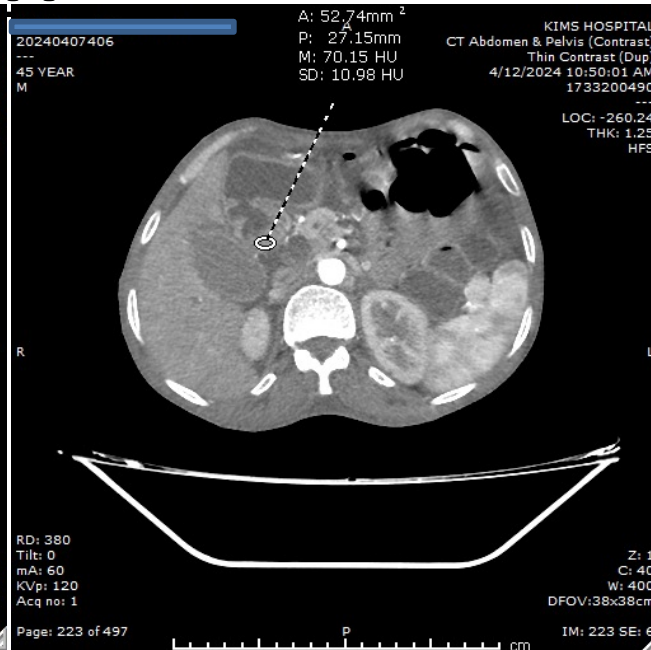
ON EXAMINATION(Cont.):

- Abdomen : Soft , Scaphoid
- **Globular swelling in right hypochondrium**
which moves with respiration(likely distended GB), Dilated veins
- **Percussion : Obliteration of liver dullness**
- PR examination: Tone - Normal, Mucosa-Normal, Roomy rectum, Mucoid stools +

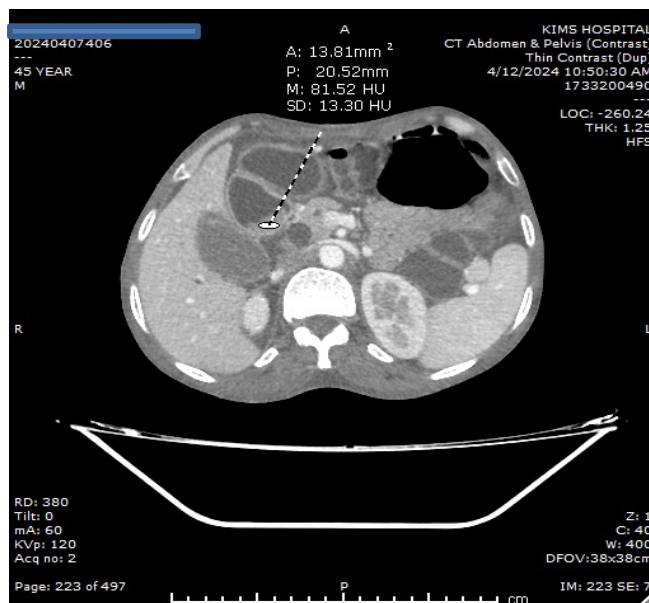
COMPUTED TOMOGRAPHY



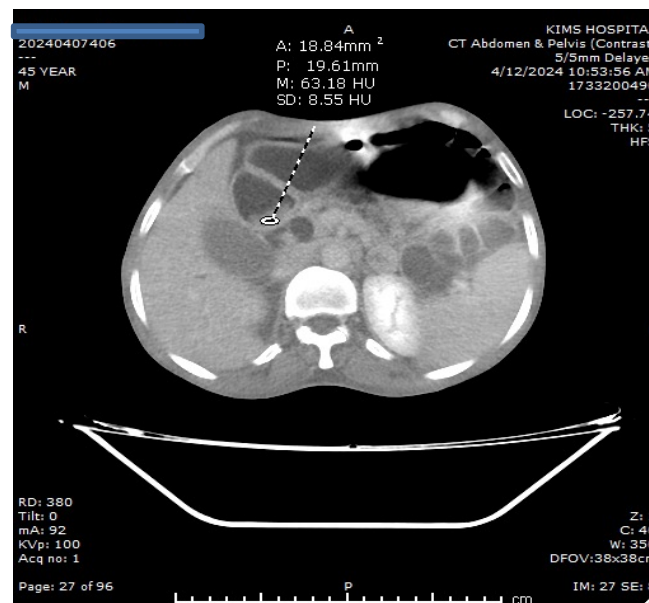
CT PLAIN



ARTERIAL PHASE



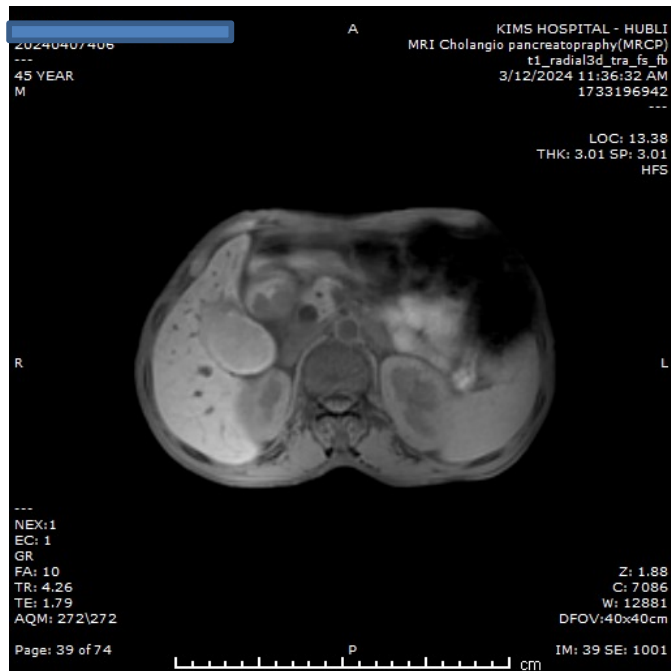
VENOUS PHASE



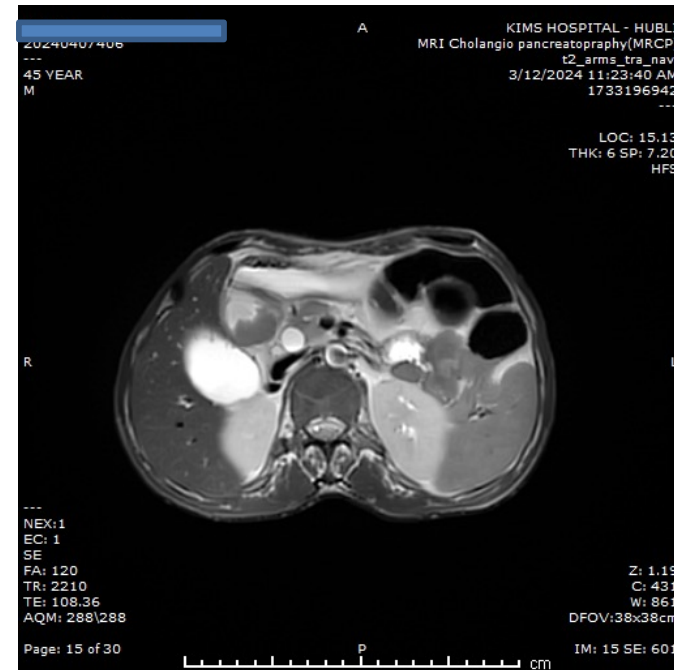
DELAYED

MAGNETIC RESONANCE IMAGING

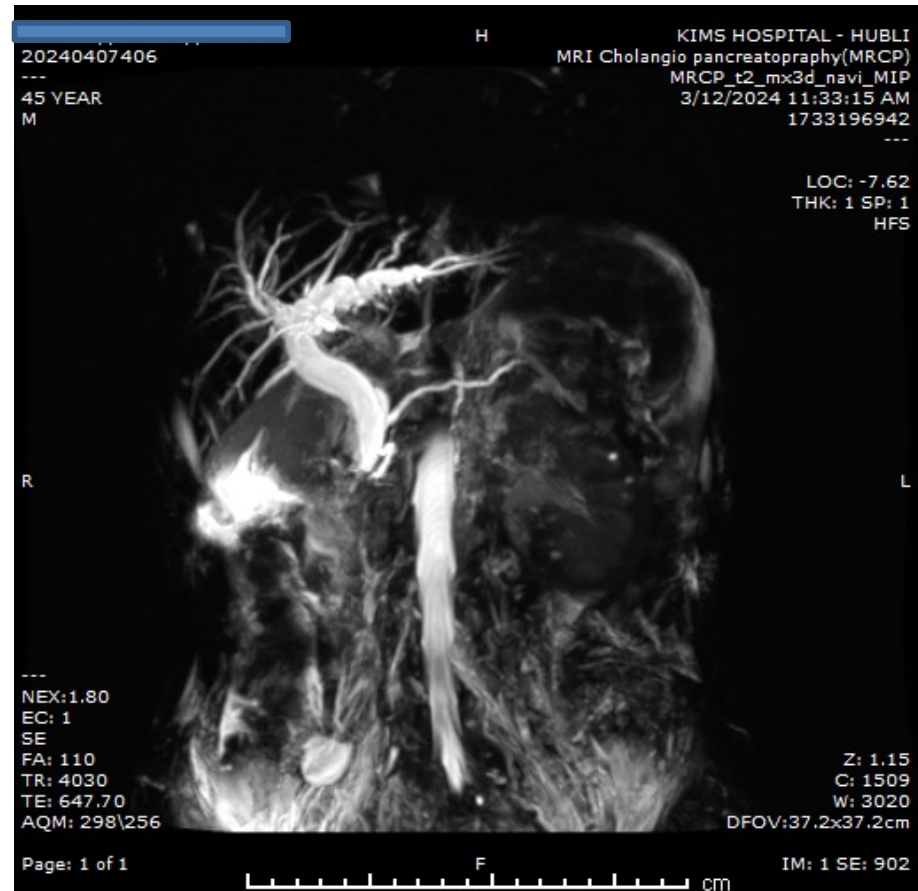
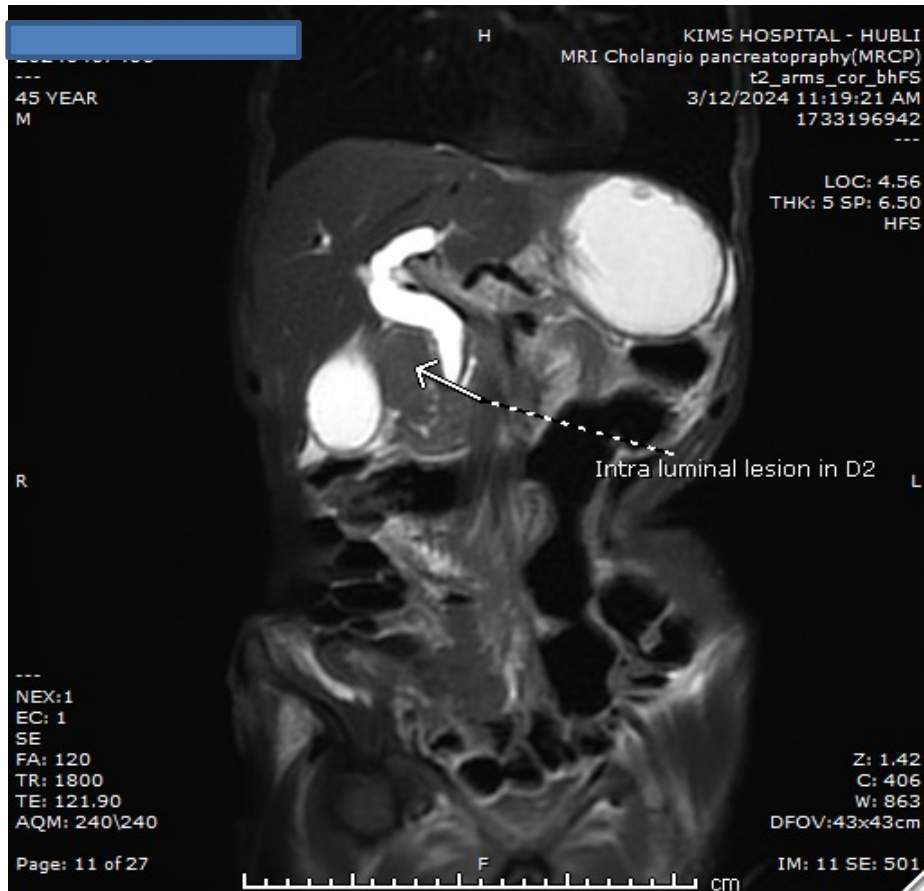
T1 AXIAL



T2 AXIAL



2nd part of the duodenum shows growth measuring 2.9x2.9 cm



Smooth tapering or narrowing of distal common bile duct secondary to D2 growth with proximal CBD dilatation measuring 12.8 mm and moderate IHBRD.

- **ENDOSCOPY: Polypoidal D2 growth with near complete occlusion of the lumen.**

