



KARNATAKA RADIOLOGY EDUCATION PROGRAM

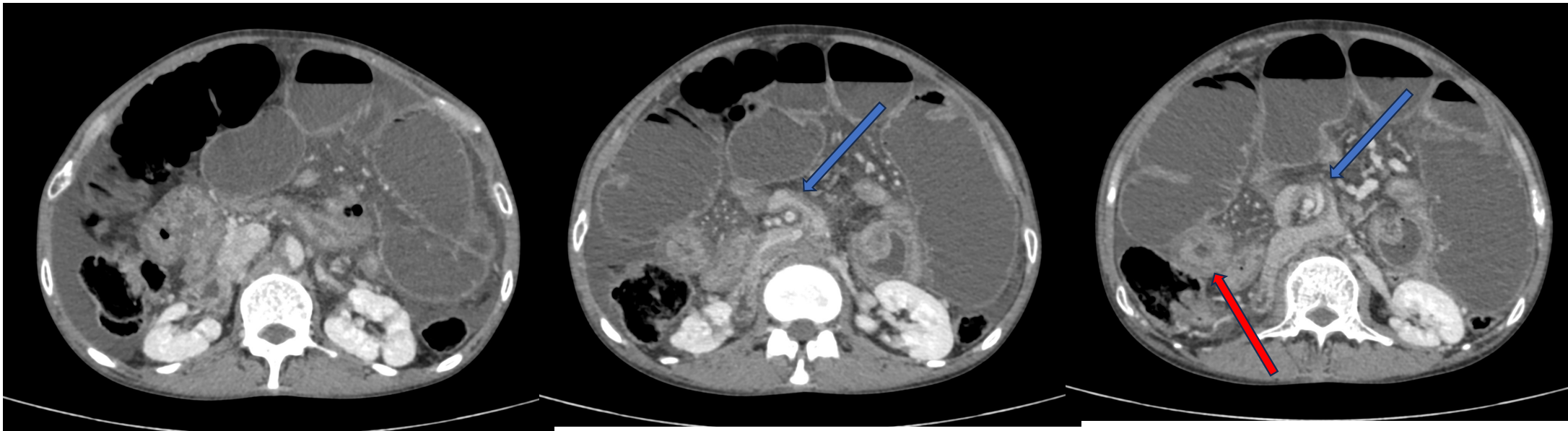
CASE PRESENTATION

*Case of Internal hernia (likely left para-duodenal)
with bowel ischemia and obstruction*

MENTOR: DR.PRADEEP S GOUDAR
KAHER UNIVERSITY
J.N.MEDICAL COLLEGE ,BELAGAVI
PRESENTER:DR. PURUSHOTHAM REDDY

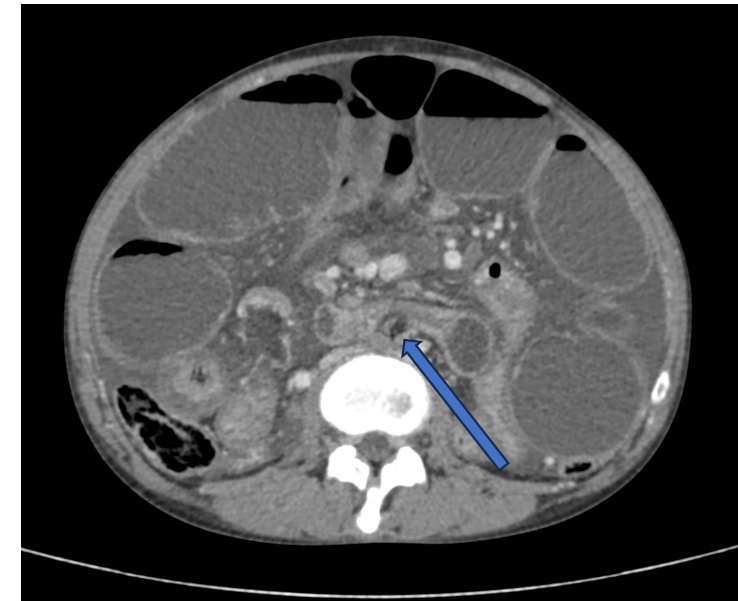
History

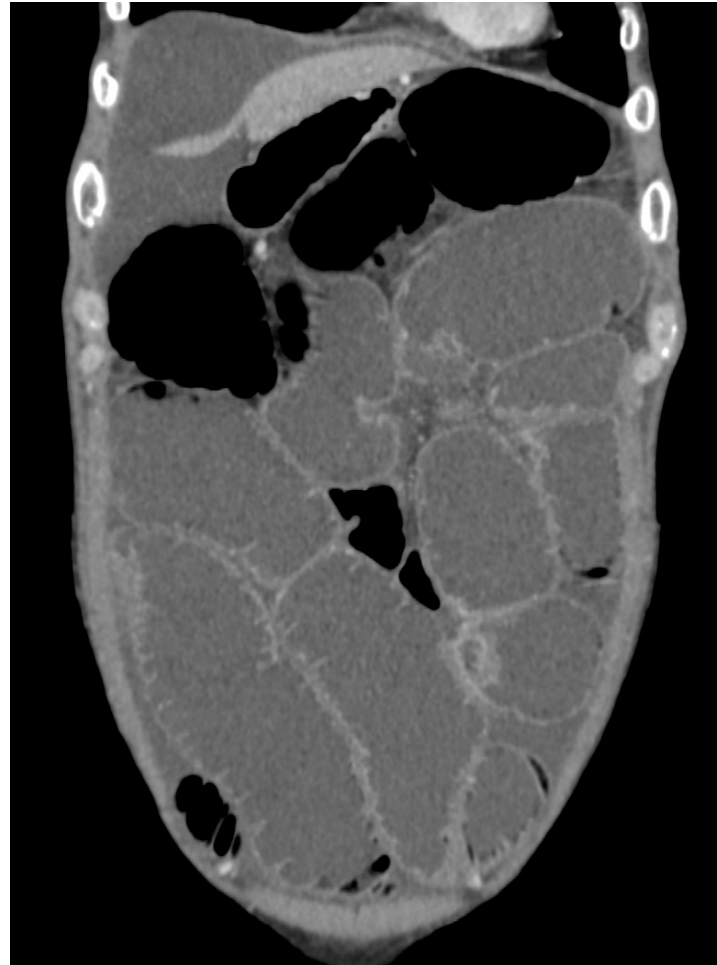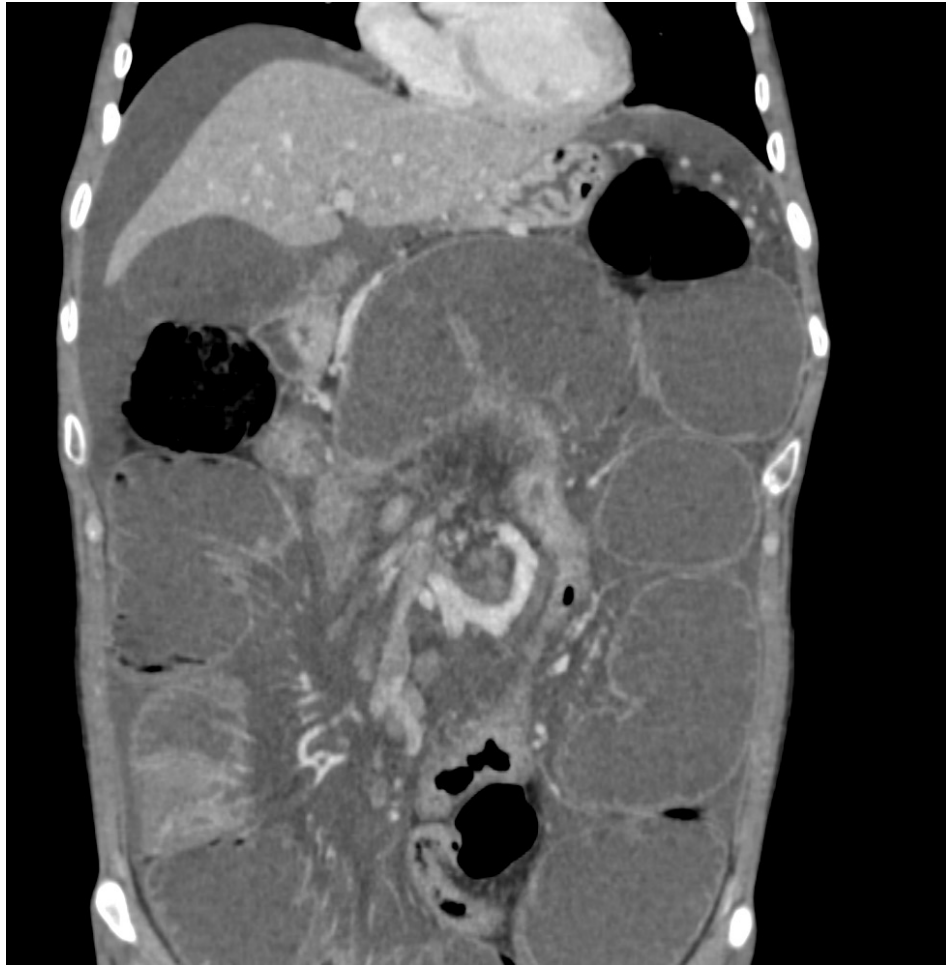- 33 year old male patient presented with abdominal pain (more in epigastric region) and abdominal distension since 2 weeks



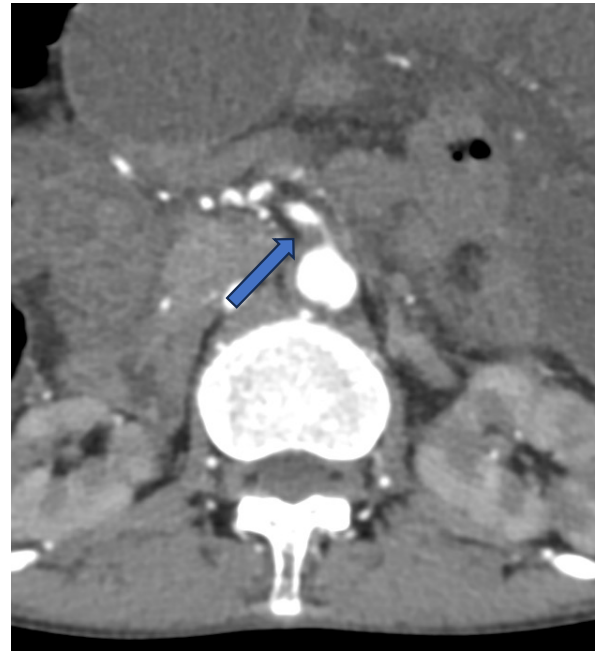
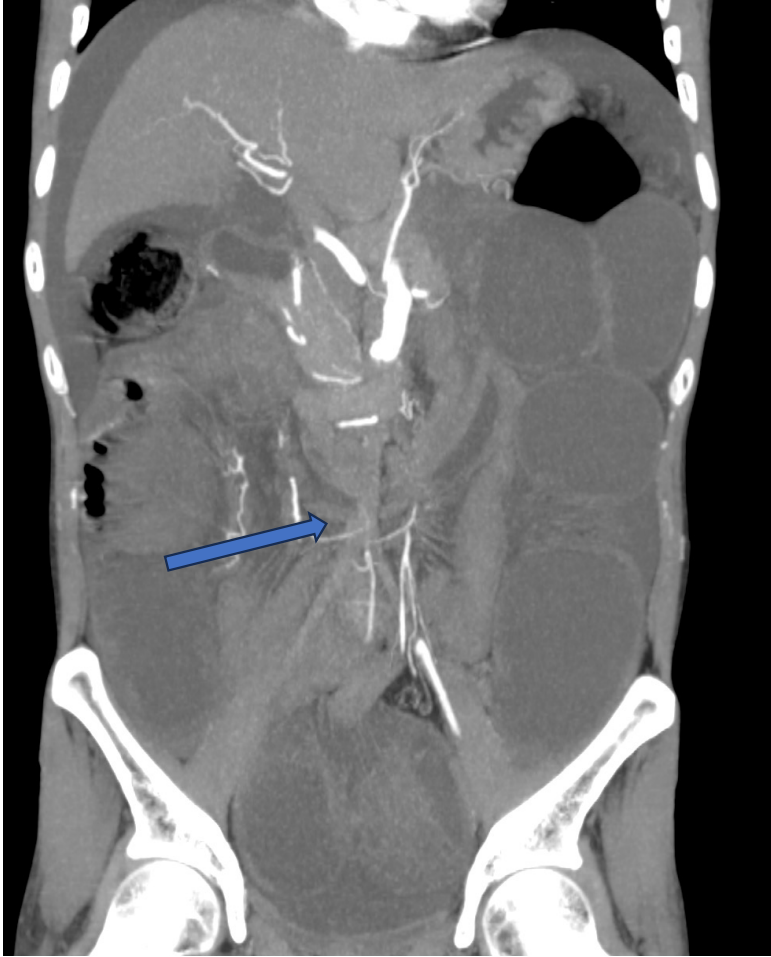VENOUS PHASE

- Twisting of D3 segment of duodenum & adjacent mesentery along the superior mesenteric vessels with herniation into the retroperitoneum likely through a left para-duodenal peritoneal defect
- Proximal and mid jejunal loops are collapsed with hypo-enhancing walls...likely suggestive of **bowel ischemia**

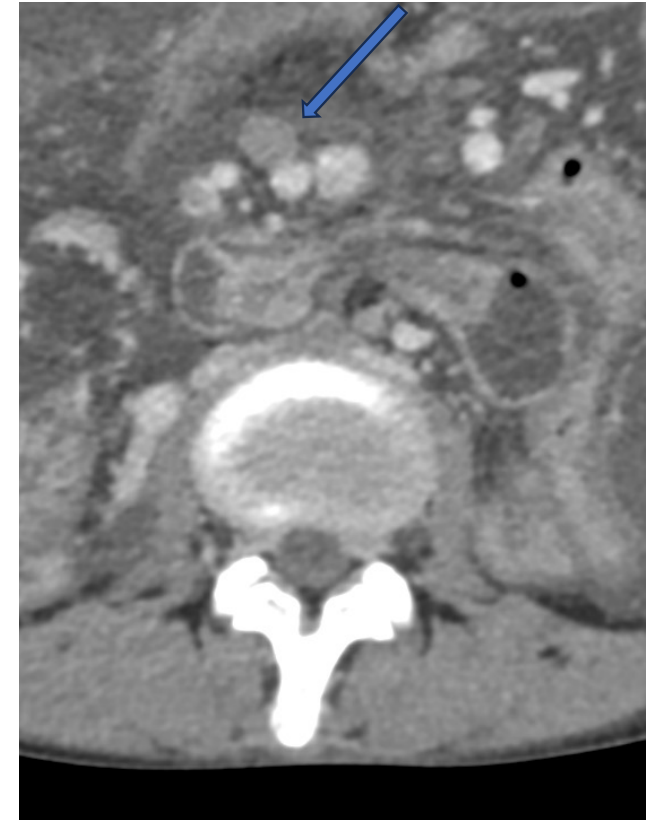




Distal jejunal and proximal & mid ileal loops appear dilated (maximum diameter measures 6.4 cm in mid ileal loops)
No obvious transition point noted.



Arterial phase- plaque extending into proximal SMA



Venous phase-
Focal thrombosis of mid SMV

Arterial phase- Concentric atheromatous plaque along the infrarenal abdominal aorta resulting in complete luminal narrowing upto the bilateral common iliac arteries and right external iliac artery

Imaging findings

- Twisting of D3 segment of duodenum & adjacent mesentery along the superior mesenteric vessels with herniation into the retroperitoneum likely through a left para-duodenal peritoneal defect
 - Bowel ischemia involving proximal and mid jejunal loops as described above
 - Dilated distal jejunal and proximal and mid ileal loops
- *Above mentioned features suggestive of internal hernia (likely left para-duodenal) with bowel ischemia and obstruction*
- Concentric atheromatous plaque along the infrarenal aorta resulting in complete luminal narrowing upto the bilateral common iliac arteries and right external iliac artery
 - Eccentric atheromatous plaque along right lateral wall of distal most supra-renal abdominal aorta extending into right lateral wall of proximal most portion of SMA resulting in 70% luminal narrowing in proximal most portion of SMA
 - Partial thrombosis involving mid superior mesenteric vein
 - Mild ascites

FOLLOW UP

Intra operative findings

- Surgery reveals Ladd band along the 3rd part of duodenum causing small bowel obstruction & internal hernia
- POD – 3, patient expired due to bowel gangrene changes